

Microchip-Induced Tumors in Laboratory Rodents and Dogs: A Review of the Literature 1990–2006

Prepared by Katherine Albrecht, Ed.D.
CASPIAN Consumer Privacy
November 19, 2007
Available online at:
<http://www.antichips.com/cancer>

Table of Contents

Abstract.....	ii
About the Author.....	ii
Problems with Microchip Implantation – And Why They Matter.....	1
Microchip-Induced Cancer in Mice and Rats.....	2
Microchip-Induced Cancer in Dogs.....	2
Microchip Studies in Which No Cancer Was Found.....	2
Animals Used in the Research.....	3
Microchips Used in the Research.....	5
Review of Studies.....	6
Microchip-Induced Cancer in Laboratory Rodents and Dogs: Eight Studies from 1996 to 2006.....	6
Le Calvez et al., 2006.....	7
Vascellari et al., 2004.....	11
Elcock et al., 2001.....	13
Blanchard et al., 1999.....	15
Palmer et al., 1998.....	18
Tillmann et al., 1997.....	19
Johnson, K., 1996.....	21
Microchip Studies In Which No Cancer Was Found.....	22
Murasugi et al., 2003.....	23
Ball et al., 1991.....	26
Rao & Edmondson, 1990.....	28
Discussion	32
Explanations for the Tumors.....	32
Differences between Species.....	35
Humans are Susceptible to Foreign-Body Carcinogenesis	35
Other Adverse Reactions to the Implants.....	37
What Do These Findings Mean for People?.....	39
Recommendations	40
For Implanted Human Patients and Their Doctors.....	40
For Policy-Makers.....	40
For Veterinarians.....	40
For Pet Owners.....	41
For Veterinary Oncology Researchers.....	41
Proposal to Create a National Registry	42
Conclusion	42
Glossary of Medical Terms.....	44
References.....	47

Abstract

This paper reviews literature published in oncology and toxicology journals between 1990 and 2006 addressing the effects of implanted radio-frequency (RFID) microchips on laboratory rodents and dogs. Eleven articles were reviewed in all, with eight investigating mice and rats, and three investigating dogs. In all but three of the articles, researchers observed that malignant sarcomas and other cancers formed around or adjacent to the implanted microchips. The tumors developed in both experimental and control animals, and in two household pets. In nearly all cases, researchers concluded that the microchips had induced the cancers.

Possible explanations for the tumors are explored, and a set of recommendations for policy makers, human patients and their doctors, veterinarians, pet owners, and oncology researchers is presented in light of these findings.

About the Author

Dr. Katherine Albrecht is widely recognized as one of the world's leading experts on consumer privacy. She regularly counsels policy makers and the media on the privacy, societal, and civil liberties impacts of new technologies, with an emphasis on RFID and retail issues. She has advised the Federal Trade Commission, various state legislatures, the Federal Reserve Bank, the European Commission, and the Office of the Canadian Privacy Commissioner, among others, and was recently appointed by NH Governor John Lynch to serve on that state's two-year RFID study commission. Dr. Albrecht is co-author of the book "Spychips: How Major Corporations and Government Plan to Track Your Every Move with RFID" with Liz McIntyre. She is the Director of CASPIAN (Consumers Against Supermarket Privacy Invasion and Numbering), a 15,000-member organization she founded in 1999 to advocate free-market, consumer-based solutions to the problem of retail privacy invasion. She holds a Doctorate in Education from Harvard University, with a research focus in consumer education, privacy and psychology.

Problems with Microchip Implantation – And Why They Matter

Since their introduction in the late 1980's, implantable microchips have become the industry standard for identifying mice and rats used in laboratory research. Animal shelters and veterinarians now routinely inject microchips into dogs and cats. More recently, there has been a push to implant microchips into people for security and building access, to manage medical records, and to identify elderly patients.

American workers at the now-defunct CityWatcher surveillance company (VeriChip Corp., 2006) and officials with the Mexican Attorney General's office (Applied Digital Solutions, 2004) have been microchipped. Concern that the practice could spread has raised the specter of Big Brother and prompted lawmakers in three states to pass laws preventing the forced or coerced implantation of microchips in human beings.¹

Throughout the controversy, the question of whether or not it is safe to implant a microchip into human flesh has not been extensively raised. When the FDA approved the VeriChip human implant in October 2004, the public believed that the device had been thoroughly tested and found to be safe.

However, a series of studies dating back to 1996 shows a link between the microchips and cancer in laboratory mice and rats. These articles received very little attention outside of toxicology laboratories until September 2007, when The Associated Press published an article that brought the studies to the attention of the American public and the world at large (Lewan, 2007).

There is now an ongoing debate regarding the safety of the chips. As a result of lobby pressure combined with heavy advertising by Schering Plough for its HomeAgain pet recovery system, close to 5% of the United States' estimated 164 million dogs and cats have now been chipped (Banfield the Pet Hospital, 2005). Animal shelters around the United States are routinely chipping dogs and cats before releasing them for adoption, and governments, including those of Portugal, Singapore, Bangkok, Los Angeles County, and El Paso, Texas, have passed ordinances requiring that all dogs under their jurisdiction be microchipped. El Paso has extended the chipping mandate to cats and ferrets, as well.

In addition, horses around the nation are also being chipped, and the USDA recently approved the use of equine radio-frequency identification (RFID) injectable transponders as part of the National Animal Identification System (NAIS).²

As for human beings, an estimated 300 Americans and 2,000 people worldwide have been implanted with microchip transponders. This chipping apparently proceeded with the full consent of the implantees until early 2007, when the VeriChip Corporation began implanting Alzheimer's patients and their caregivers with microchips as part of a research study. These patients have reduced mental capacity and are unlikely to understand what is being done to them.

It appears that few people undergoing microchip implantation have been told about the potential health risks associated with the device. In fact, up until September 2007, almost three years after FDA approval, no mention had been made by the company or the FDA in relation to the well-established,

1 California, Wisconsin, and North Dakota have all passed laws banning forced or coerced microchip implantation in human beings. See: California SB 362 (2007), Wisconsin AB 290 (2005), and North Dakota SB 2415 (2007).

2 The National Animal Identification System (NAIS) is a national premises registration, animal identification, and animal tracing program for owners of livestock. NAIS is a national program run by the United States Department of Agriculture (USDA), but is being implemented primarily at the state level.

though generally under-reported, finding that the microchip caused cancer in laboratory mice and rats.

Microchip-Induced Cancer in Mice and Rats

In at least six studies published in toxicology and pathology journals between 1996 and 2006, researchers found a causal link between implanted microchip transponders and cancer in laboratory mice and rats. The tumors were typically sarcomas, including fibrosarcomas. Other cancers found included rhabdomyosarcoma, leiomyosarcoma, malignant fibrous histiocytoma, mammary gland adenocarcinoma, malignant schwannoma, anaplastic sarcoma, and histiocytic sarcoma.

In almost all cases, the tumors arose at the site of the implants and grew to surround and fully encase the devices. In several cases the tumors also metastasized or spread to other parts of the animals, including the lungs, liver, stomach, pancreas, thymus, heart, spleen, lymph nodes, and musculature of the foreleg.

The tumors generally occurred in the second year of the studies, or after half a lifetime's exposure to the implant. At the typical time of tumor onset the animals were in middle to advancing age. The exception to this was the Blanchard (1999) study, in which genetically modified mice developed fast-growing cancers well before six months.

The percent of mice and rats developing microchip-induced tumors in the six studies reviewed ranged from 0.8% to 10.2%. Several researchers, including Elcock et al. (2001), Le Calvez et al. (2006), and Tillmann et al. (1997) suggest that the actual rate of tumor formation may have been higher than what was reported in their studies, since they examined only visible lesions and thus may have missed microscopic changes that signaled the onset of additional tumors around the implants.^{3,4,5}

Microchip-Induced Cancer in Dogs

In addition to the six studies that identified cancer in rodents, two studies evaluated cancerous tumors (fibrosarcoma and liposarcoma) that developed in dogs at the site of microchip implants. In one case, the tumor was attached to the implant. In the other case, the tumor completely encased the microchip.

Microchip Studies in Which No Cancer Was Found

Included in this review are three studies, one involving dogs, one involving rats, and one involving mice, in which none of the animals developed cancer from the microchip implant. Though these studies were originally presented as evidence that implantable microchip devices were safe, they suffer from methodological limitations that call their statistical validity into question. These limitations include the small number of animals used and the short duration of the studies. Those issues are discussed at further length in this document.

3 Elcock et al. write "It should be noted...that these tumor incidences only approximated the potential incidence of microchip-induced tumors for these studies. The original intent of the studies was to characterize the toxicological profile of the chemical test substance in question, therefore tissue surrounding the animal-identification microchips was not examined microscopically unless there was a gross lesion. Thus, small pre-neoplastic or neoplastic lesions may have been missed." (p. 488)

4 A similar observation was made by Le Calvez et al. (2006). In their study 4.1% of animals developed visibly detectable tumors, while researchers suspected the actual incidence of cancer may have been higher had they looked at tissue samples.

5 Tillmann et al. (1997) also write that "only implantation areas with macroscopic findings have been examined microscopically, so that possible pre-neoplastic lesions could have been missed." (p. 200)

Overall Cancer Incidence

Tables 1 and 2 below summarize the results of the 11 studies reviewed herein. Table 1 lists the cancer incidence from eight studies where cancer was found in connection with a microchip implant. Table 2 lists details from the three studies in which no cancer was found.

Table 1. Studies that found microchip-induced cancer (in reverse chronological order)

Author(s)	Species	# of animals	Length of Implant Exposure	Developed Cancer
Le Calvez et al., 2006	mice	1,260	2 years	4.1%
Vascellari et al., 2006	dog	N/A	7 months (at age 9)	1 dog
Vascellari et al., 2004	dog	N/A	18 months (at age 11)	1 dog
Elcock et al., 2001	rats	1,040	2 years	0.8%
Blanchard et al., 1999	mice	177	6 months	10.2%
Palmer et al., 1998	mice	800	2 years	2.0%
Tillmann et al., 1997	mice	4,279	lifespan	0.8%
Johnson, 1996	mice	2,000	2 years	~1.0%

Table 2. Studies that did not find microchip-induced cancer (in reverse chronological order)

Author(s)	Species	# of animals	Length of Implant Exposure	Developed Cancer
Murasugi et al., 2003	dogs	2	3 days	none observed
		2	3 months	
		2	1 year	
		2	3 years	
		1	6 years	
Ball et al., 1991	rats	10	2 weeks	none observed
		10	3 months	
		10	6 months	
		10	1 year	
Rao & Edmondson, 1990	mice	10	3 months	none observed
		10	15 months	
		74	2 years	
		39	< 2 years	

Animals Used in the Research

Toxicology and carcinogenicity researchers rely on laboratory animals to help determine which substances are safe and which are potentially harmful. Since most substances that cause cancer in humans also cause cancer in mice and rats, these animals can serve as an early indicator that a substance may not be safe for use in humans.

Several different strains of laboratory mice and rats were evaluated in the rodent studies reviewed in this report, including B63F1 mice, CBA/J mice, p53+/- transgenic mice, Fischer 344 rats, and Sprague-Dawley rats. The dogs involved in studies included one beagle, one French bulldog, and

several mixed-breed dogs. A listing of the animals involved in each research study has been provided in Table 3 below.

Table 3: Animals examined in the studies, identified by breed or strain

Author(s)	# of Animals	Type of Animal Studied	Developed Cancer
Le Calvez et al., 2006	1,260	B6C3F1 mice	4.1%
Elcock et al., 2001	1,040	Fischer 344 rats	0.8%
Blanchard et al., 1999	177	p53+/- transgenic mice	10.2%
Palmer et al., 1998	800	B6C3F1/CrIBR VAF/Plus mice	2.0%
Tillmann et al., 1997	4,279	CBA/J mice	0.8%
Johnson, 1996	2,000	B6C3F1 mice and CD1 ("albino") mice	~1.0%
Murasugi et al., 2003	9	Beagle; mixed breed dogs	none observed
Ball et al., 1991	40	Sprague-Dawley rats	none observed
Rao & Edmondson, 1990	140	B6C3F1 mice	none observed
Vascellari, 2006	1	French bulldog	1 dog
Vascellari, 2004	1	Mixed breed dog	1 dog

Animals in the first group of studies above developed microchip-induced tumors. Animals in the second group did not develop tumors. The third group of studies pertain to dogs that developed cancer around or attached to microchip implants.

Rodents used in laboratory studies are specially bred for uniformity and hardiness. They are utilized in cancer studies for their ability to respond to carcinogenic substances while remaining relatively free from spontaneous tumors that are unrelated to carcinogenic test substances.

The B6C3F1 mouse was the most commonly used mouse in these studies, appearing in four of the eight rodent studies. The Handbook of Carcinogen Testing (Milman & Weisburger, 1994) states that National Toxicology Program studies use the B6C3F1 mouse almost exclusively for cancer research because of its desirable characteristics. The Handbook describes the mouse as "hardy, easy to breed, disease resistant, and [having] a low spontaneous tumor incidence at most sites." (p. 353)

The p53+/- mouse contains a genetic mutation in the p53 gene which normally sends protein to help repair damaged cells. In these mice, one allele, or portion of the gene has been deleted, thus increasing their susceptibility to cancer caused by genotoxins, or substances that damage genetic material. p53+/- mice are not known to develop spontaneous cancers in the first six months of life and are expected to only develop cancer in the presence of genotoxins. The high rate of cancer development around the microchip implant in p53+/- mice at less than six months suggests that the implant may have genotoxic attributes.

The CBA/J mouse is an inbred strain that is widely used as a general purpose laboratory animal. It suffers from hereditary blindness, making it of interest to vision researchers, and it is often selected for other studies because of its low incidence of mammary tumors (The Jackson Laboratory). The CD-1 (albino) mouse is described as a "general multipurpose model [for] safety and efficacy testing, aging, surgical model, [and] pseudopregnancy" (Charles River Laboratory, 2007, p. 15).

The Sprague-Dawley rat is described as "a general model for the study of human health and disease" and an "excellent model for toxicology, reproduction, pharmacology, and behavioral research areas." They have a life span of 2.5 – 3.5 years (Ace Animals, Inc., 2007).

The Fischer 344 rat is described as the "most widely used inbred rat strain, particularly for toxicology and teratology" studies (Simonsen Laboratories, 2007).

Microchips Used in the Research

The glass used to encapsulate the microchip is known as "bioglass," a material widely used in animal studies due to its insolubility and apparent biocompatibility (Vascellari et al., 2004). Bioglass is comprised primarily of "silicon, sodium, calcium, potassium, magnesium, iron, and aluminum" and has been classified in the silicon sodium group (Vascellari et al, 2004, p. 188; citing Jansen et al., 1999).

The microchip transponder comes prepackaged in a sterile 12-gauge injection needle attached to an implantation device supplied by the manufacturer. Once the transponder is embedded in the body, it can be interrogated by a reader device that emits radio-frequency energy. This energy stimulates the embedded transponder, causing it to emit a signal that is captured by the scanner and translated into an identification code.

The microchips used in these studies were obtained from several distributors, including BioMedic Data Systems, Inc., Destron Fearing, and Merial, as indicated in the table below.

Table 4. Microchip implants used in the studies, identified by brand name or supplier

Author(s)	Microchip used	Developed Cancer
Le Calvez et al., 2006	BioMedic Data Systems Inc.	4.1%
Elcock et al., 2001	BioMedic Data Systems Inc.	1.0%
Blanchard et al., 1999	BioMedic Data Systems Inc.	10.2%
Palmer et al., 1998	Unspecified	2.0%
Tillmann et al., 1997	BioMedic Data Systems Inc.	0.8%
Johnson, 1996	BioMedic Data Systems Inc.	~1.0%
Murasugi et al., 2003	LifeChip; Destron Fearing.	none observed
Ball et al., 1991	BioMedic Data Systems Inc.	none observed
Rao & Edmondson, 1990	BioMedic Data Systems Inc.	none observed
Vascellari, 2006	Merial Indexel® (Digital Angel)	1 dog
Vascellari, 2004	Merial Indexel® (Digital Angel)	1 dog

Animals in the first group of studies developed microchip-induced tumors, whereas animals in the second group did not develop tumors; the third group of studies pertains to dogs that developed cancer around or attached to the microchip implants.

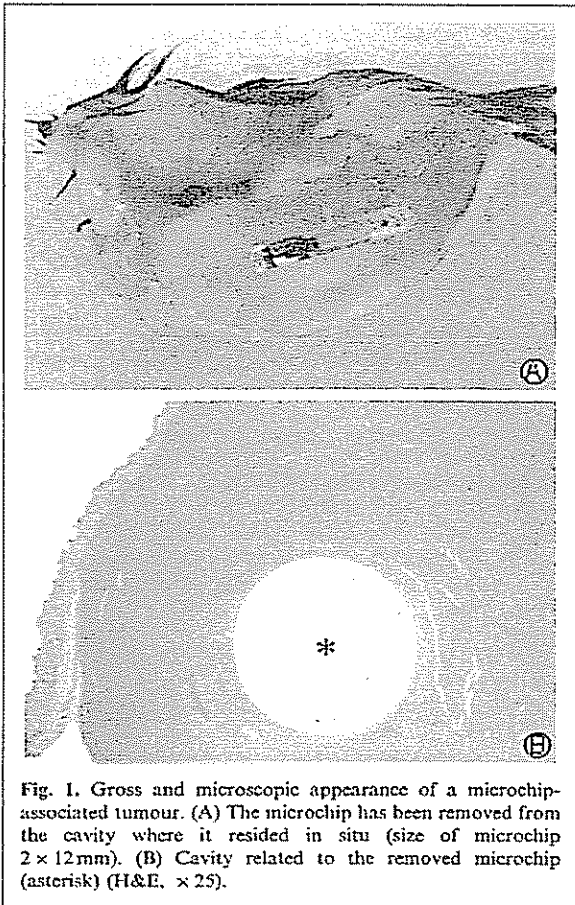
Review of Studies

**Microchip-Induced Cancer in Laboratory Rodents and Dogs:
Eight Studies from 1996 to 2006
(Presented in reverse chronological order)**

Le Calvez et al., 2006

Subcutaneous microchip-associated tumours in B6C3F1 mice: A retrospective study to attempt to determine their histogenesis. *Experimental and Toxicologic Pathology*. 2006;57:255–265.

Author(s)	# of Animals	Species	Study Length	Developed Cancer
Le Calvez et al., 2006	1,260	mice	2 years	4.1%



"Most of the animals with microchip-associated tumors died prematurely...due to the size of the masses [or] the deaths were spontaneous and attributed to the masses." (p. 258)

"One of the most potentially serious disadvantages of the microchip implantation is the possibility that foreign-body-induced tumours may develop..." (p. 256)

Summary of Study

Microchips were implanted into 1,260 experimental mice for identification purposes. Two years later, 4.1% of the mice had developed malignant (cancerous) tumors at the site of the microchip implantation. The cancers were directly attributed to the microchips. In one subgroup, the cancer rate among the chipped mice was 6.2%.

Study Design and Key Findings

1,260 mice were separated into groups for use in three oral carcinogenicity studies. The first study involved 550 mice, 110 of which received only a microchip implant. The other 440 received a microchip implant along with a low, medium, or high dose of a chemical test substance in their feed.

Two years later, 34 of the mice (6.2%) had developed malignant (cancerous) tumors around or adjacent to the microchip. These tumors occurred across groups, appearing in control mice as well as mice that had received the ingested chemical. Researchers plainly identified the microchip as the cause of the tumors.

The second study involved 600 mice. 120 received only a microchip, while the other 480 received a microchip combined with varying doses of a chemical compound in their feed. Two years later, 14 out of the 600 mice (2.3%) had developed cancerous tumors related to the microchip. For the test group of 480 mice, these tumors were determined to be unrelated to the ingested compound.

In the third study, 110 mice were implanted with a microchip and received no other intervention. Four of these animals (3.6%) developed a tumor around the microchip.

The researchers suggest the actual cancer rate may have been higher than what they reported, as they tested for cancer only when visible abnormalities were seen in the mice. Smaller tumors in the early stages of development that were not yet visible to the naked eye may have been missed.⁶

Additional findings

- All of the cancerous masses found either contained the microchip or were adjacent to it. An empty capsule where the microchip had been was frequently identified as the origin of the tumor.⁷ Figure 1 from the article (reproduced on the previous page) illustrates this phenomenon.
- Tumors were initially identified by morphology as fibrosarcoma (17 cases), rhabdomyosarcoma (12 cases), leiomyosarcoma (2 cases), malignant fibrous histiocytoma (3 cases), mammary gland adenocarcinoma (2 cases), and other sarcomas (16 cases). Researchers later redefined the tumors as "sarcomas not otherwise specified (NOS) with a large myofibroblastic component" (p. 255) after additional testing. A sarcoma is a malignant tumor of soft tissue that connects, supports or surrounds other structures and organs of the body.
- Once initiated, the tumors grew rapidly. Most of the animals that developed microchip-associated tumors died prematurely as a result of the tumors.
- Four microchip-related cancers metastasized (spread) to the lungs, liver, stomach or pancreas.
- Many of the implants migrated from the original implantation site on the back of the mice to cause cancer at other locations in the body. Nineteen percent of the cancers found involved microchips that had migrated from the back to the limbs, abdomen, or head of the mice.
- A test procedure known as desmin staining found that the tumors often infiltrated nearby muscle tissue and that there was "an extensive cavernous network of capillaries within the tumour, especially around the hole left by the microchip." (p. 261)

Study Details

- The study was conducted at MDS Pharma Services in L'Arbresle, France.
- Animals used in the study were B6C3F1 mice from Charles River Laboratory.
- Microchip implants were from BioMedic Data Systems Inc. and were described as "hermetically sealed in a cylindrical inert glass capsule measuring 12 mm in length and 2 mm in diameter and partially covered on a length of 5 mm by a porous polypropylene polymer sheath as an antimigration measure." (p. 255)

6 The authors write that "as these were only sampled and examined histologically when gross abnormalities were noted, it is possible that early reaction could have been missed. These incidences may therefore slightly underestimate the true occurrence." (p. 258)

7 The researchers wrote: "All sarcomas were characterized by a poorly delineated, non-encapsulated, densely cellular mass, located in the subcutis but frequently infiltrating the panniculus muscle and various layers of the skin with occasional ulcerations. A round-to-oval empty space of 2 mm diameter corresponding to the cast of the microchip was frequently seen and associated with a vestigial fibrous capsule and/or a focus of necrosis." (p. 261)

Vascellari, Melchiotti, & Mutinelli, 2006

Fibrosarcoma with typical features of postinjection sarcoma at site of microchip implant in a dog: Histologic and immunohistochemical study. *Veterinary Pathology*. 2006;43:545–548.

Author(s)	Animal Involved	Chip Exposure Time	Cancer Developed
Vascellari, et al., 2006	9-year-old French bulldog	7 months	Fibrosarcoma



"Reports on adverse reactions to vaccination and microchips are strongly encouraged to deepen the current knowledge on their possible role in tumorigenesis . . . the cause and effect relationship between exposure (injection) and outcome (sarcoma) is still to be defined and is a matter of discussion for experts." (p. 547)

Summary

A 9-year-old bulldog developed a cancerous tumor (fibrosarcoma) adjacent to a microchip implant approximately seven months after being implanted with the device. Researchers attributed the tumor to either the microchip or to vaccinations at the site, and called for better reporting of adverse reactions to microchip implants and vaccinations.

Overview

In September 2003, Leon, a 9-year-old male French bulldog was implanted with a microchip for identification purposes. In April 2004 (8 months later) Leon's owner detected a lump measuring 3 cm x 3 cm (1.2 x 1.2 inches) in the implant area. The mass was surgically removed and subjected to laboratory analysis whereby it was identified as a high-grade infiltrative fibrosarcoma—a malignant and fast-growing form of cancer. It was found attached to the microchip. Leon later died from complications that his owner attributes to the cancer.

The microchip is implanted into dogs through an injection procedure involving a 12-gauge needle. The researchers suggest the tumor may be a form of post-injection sarcoma, involving an inflammatory reaction around an injection site that predisposes the tissues to tumor development. The researchers note that "irritation, inflammation, and/or wounds [promote] tumor development. Virtually anything that causes a local inflammatory reaction may potentially be responsible for neoplastic initiation [i.e., abnormal proliferation of cells]." (p. 546)

The authors attributed the cancer to either the microchip or to vaccinations the dog had received at the same site. They wrote: "It is difficult to establish which was the primary cause of the neoplastic growth, because the dog had received several rabies vaccines and the microchip was detected close to but not included in the mass." (p. 547)

The investigators conclude by stating that "reports on adverse reactions to vaccination and microchips are strongly encouraged to deepen the current knowledge on their possible role in tumorigenesis [causing tumors]," calling it "a matter of discussion for experts." (p. 547)

It should be noted that a complete physical exam found nothing other than the detected lump to indicate that Leon had developed cancer. No evidence of inflammation or sepsis were found at the site of the implant. Had Leon's owner not insisted on a microscopic evaluation of the unusual growth, his cancer might never have been detected.

Study Details

- The evaluation was conducted by Dr. Marta Vascellari of the Istituto Zooprofilattico Sperimentale delle Venezie at Viale dell'Università in Legnaro, Italy, with associates Erica Melchioni and Franco Mutinelli.
 - The microchip was manufactured by Digital Angel,⁸ the parent company of the VeriChip Corporation. It was distributed by Merial⁹ under the Indexel® brand, through Lyon, France.
-

8 Digital Angel's website states: "Digital Angel manufactures implantable RFID chips used in pets around the world.... In Europe, our product is distributed by Merial in some countries under the Indexel® brand. For more information, visit [merial.com](http://www.digitalangelcorp.com/dac_pets.asp)." Source: http://www.digitalangelcorp.com/dac_pets.asp. Accessed July 23, 2007.

9 Merial's website states: "Merial is a world-leading animal health company. We are a forward-looking company with a proven track record, producing pharmaceutical products and vaccines for livestock, pets and wildlife." Source: http://www.merial.com/our_company/index.asp. Accessed July 23, 2007.

Vascellari et al., 2004

Liposarcoma at the site of an implanted microchip in a dog. *The Veterinary Journal*. 2004;168:188–190.

Author(s)	Animal Involved	Chip Exposure Time	Cancer Developed
Vascellari et al., 2004	11-year-old mixed breed dog	19 months	liposarcoma

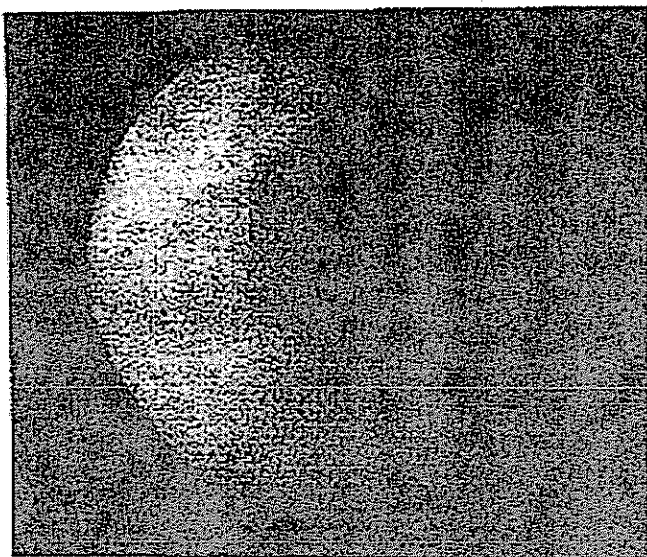


Fig. 1. The microchip was detected in the subcutaneous fascia, at the basis of the neoplastic mass, by image intensifier.

"The intact microchip was found completely embedded within the mass . . . [and] a diagnosis of low-grade liposarcoma was made."
(p.188)

"Veterinary surgeons are . . . encouraged to check the microchips that have been implanted in pets at least annually, such as when they come in for vaccinations, and report any adverse reaction." (p. 190)

Summary of Study

An 11-year-old dog developed a cancerous tumor (liposarcoma) around a microchip that had been implanted approximately 19 months earlier. The tumor was removed and the dog recovered.

Overview

In April 2000, a male mixed-breed dog was implanted with a microchip for identification purposes. In November 2001 (19 months later) the dog's owner detected a firm, painless lump at the implant site measuring 10 x 6 cm (approximately 4 x 2.5 inches). The lump was examined by a veterinarian who determined that the microchip was completely embedded within the mass.

In April 2003, the tumor was surgically removed under general anesthesia. Upon microscopic examination, it was identified as a malignant liposarcoma, an aggressive and invasive type of cancer that can metastasize to the lungs, liver, and bone. The researchers note that liposarcoma is uncommon in dogs.

Prior to the surgery, the dog had shown no visible signs of cancer other than the unusual lump. Blood tests run on the dog, including a complete pre-operative blood count and serum biochemistry analysis, did not detect that the mass was malignant. Thoracic radiographs (chest X-rays) were also normal. Had there not been a microscopic evaluation of the unusual growth, the cancer might not have been detected.

Study Details

- The evaluation was conducted by Dr. Marta Vascellari and Franco Mutinelli of the Istituto Zooprofilattico Sperimentale delle Venezie, Histopathology Department, in Legnaro, Italy, together with veterinary surgeons Romina Cossettini and Emanuela Altinier of Porcia, Italy.
 - The microchip was manufactured by Digital Angel, the parent company of the VeriChip Corporation. It is distributed by Merial under the Indexel® brand. Researchers state that the implant "consists of a sealed glass capsule containing a chip and a coil . . . [and is] equipped with an anti-migrational capsule, located in the anterior part of the microchip."
-

Elcock et al., 2001

Tumors in long-term rat studies associated with microchip animal identification devices. *Experimental and Toxicologic Pathology*. 2001;52:483–491.

Author(s)	# of Animals	Species	Study Length	Developed Cancer
Elcock et al., 2001	1,040	rats	2 years	0.8%


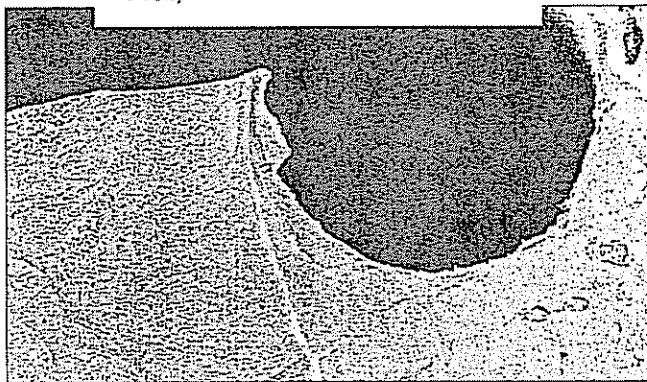


Fig. 2. Gross appearance of a microchip-associated tumor. The microchip (arrow) has been removed from the cavity where it resided in-situ (arrow-head) (female #3102).



Scanning electron micrographs of the cavity created by the microchip device:

Fig. 8. The cavity (C) is surrounded by a densely-packed tumor (fibrosarcoma), which conforms tightly to the shape of the microchip device (female #3102) (x35).

"Electronic microchip technology as a means of animal identification may affect animal moribundity and mortality [i.e., illness and death rates], due to the large size and rapid growth of microchip-induced tumors as well as the occurrence of metastases." (p. 491)

"Most tumors arising from foreign bodies are malignant . . . and have a rapid growth rate, killing the animal in a matter of weeks." (p. 491)

Summary of Study

1,040 rats were implanted with microchip implants for identification purposes. After two years, just under 1% developed malignant tumors (malignant schwannoma, fibrosarcoma, anaplastic sarcoma, and histiocytic sarcoma) surrounding the implants. The researchers attributed the tumors to the presence of the microchip, and referred to them as "microchip-induced."

Study design and key findings

1,040 rats¹⁰ were implanted with a microchip transponder then divided into two random groups. Half were exposed to an ingested chemical compound at high, medium, and low doses; the other half received no compound. By the end of the second year, eight of the rats that received the compound, or 0.77%, had developed malignant tumors at the site of the microchip implant.

Though the affected rats had all been dosed with a test substance, the tumor incidence was distributed across dose groups and

10 The study originally involved 1,200 rats, but various factors reduced the final count to 1,040.

showed no test-substance-related trends. Stated slightly differently, higher levels of chemical compounds in the animals' feed did not correspond to higher tumor rates.

Further clarifying that the tumors had arisen in response to the microchips, not the test compound, the investigators wrote: "the process of differentiating microchip-induced tumors from suspected compound-related tumors was fairly easy in the cases described here, for all contained the embedded microchip device." (p. 491)

Additional findings

- The microchip-induced tumors were identified as malignant schwannoma, fibrosarcoma, anaplastic sarcoma, and histiocytic sarcoma. All diagnoses were confirmed with immunohistochemistry.
- All masses were confined to the area of microchip implantation and contained embedded microchips.
- Some masses were extremely fast-growing, enlarging as much as 1 cm. per week. Several tumors metastasized to regions including the lungs, thymus, heart, lymph nodes, and musculature.
- Five of the eight affected animals died as a direct result of the microchips.
- All tumors occurred in the second year of the study. The average age at tumor onset was 585 days, or approximately one year and seven months. (The average life span of a rat is two to three years.)
- The researchers write that: "Although the resulting tumor rate was observed to be low, the overall health of the affected rats was compromised due to tumor size and the occurrence of metastases, leading to early sacrifice." (p. 484) In other words, the animals' health was so poor due to large, malignant tumors spreading through their bodies that researchers were forced to kill them prematurely.

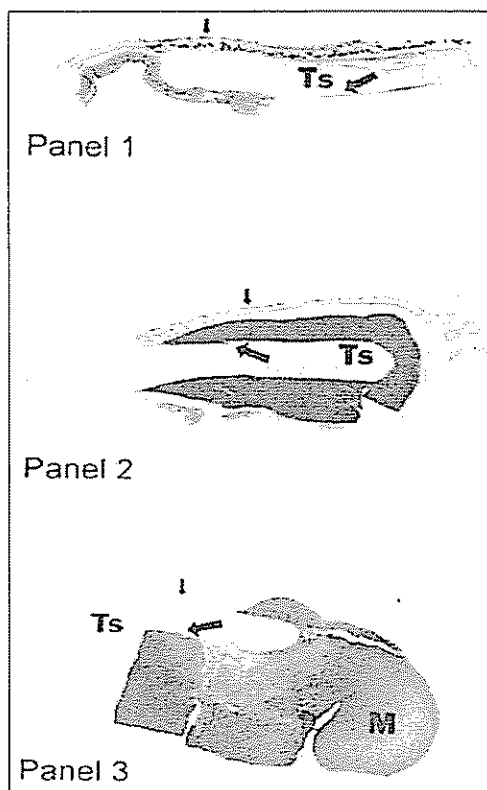
Study Details

- The study was conducted by Laura E. Elcock of Bayer Corporation in Stilwell, Kansas. Other investigators were Barry Stuart, Bradley Wahle, Herbert Hiss, Kerry Crabb, Donna Millard, Robert Mueller, Thomas Hastings and Stephen Lake. The results were peer-reviewed by an independent pathologist.
 - Animals used were Fischer 344 laboratory rats.
 - Microchip implants were from BioMedic Data Systems Inc.
-

Blanchard et al., 1999

Transponder-induced sarcoma in the heterozygous p53+/- mouse. *Toxicologic Pathology*. 1999;27(5):519–527.

Author(s)	# of Animals	Species	Study Length	Developed Cancer
Blanchard et al., 1999	177	mice	6 months	10.2%



"There was an unequivocal association between the [microchip implant] transponder and sarcoma that was unrelated to drug treatment." (p. 526)

"The presence of the foreign body [microchip transponder] may elicit tissue reactions capable of generating genotoxic byproducts." (p. 526)

FIG. 1.—Subcutaneous transponder sites in transgenic mice in unaffected stage and in various stages of tissue mass development. Panel 1: Transponder site cavity (Ts) prior to mass development. Transponder was located just beneath the skin (small arrow) and surrounded by a typical capsule membrane (large arrow) of condensed connective tissue in which mass (M) development begins. Orientation of the transponder capsule is glass extremity to the left and polypropylene extremity to the right. Panel 2: Mass development is apparent in association with the polypropylene extremity and was often observed to begin at the glass-polypropylene interface. At this stage, early mass development may or may not be macroscopically apparent. Panel 3: Fully developed mass predominantly at the polypropylene extremity. In later stages, the entire site may be involved.

Summary of Study

177 genetically modified mice were implanted with microchips for identification purposes as part of a chemical compound study. After six months, 18 of the mice (10.2%) had developed malignant tumors ("undifferentiated sarcomas") around the microchip. The tumors occurred in both experimental and control animals. The researchers reported an "unequivocal association" between the implants and the cancer.

Study design and key findings

177 transgenic p53+/- mice¹¹ were implanted with microchips as part of a six-month study to

¹¹ These mice are genetically modified to have a higher rate of cancer development when exposed to genotoxicants but to be insensitive to nongenotoxins. The glass and polypropylene components of the BioMedic transponder device are generally assumed to be free from genotoxic materials (mutagenic and/or cytotoxic components), so an observation of tumors would not be predicted by this model. (p525)

investigate the toxicity of various chemical compounds. After six months, 18 of the mice (10.2%) developed malignant tumors ("undifferentiated sarcomas" p. 520) around the microchip. The tumors occurred in both control animals and animals that had received the test compound. The authors wrote that "these masses were not related to test substance administration; they were observed in controls as well as dosed animals." (p. 520)

Of the 177 total mice studied, 56 died before researchers made a link between the microchip and the tumors. The tissue surrounding the implants in the remaining 121 mice was microscopically analyzed.

Researchers discovered that the tumors arose at the microchip's plastic anchoring barb and then expanded to eventually surround the entire microchip. They state: "It appeared that tumor(s) arose in the mesenchymal tissue surrounding the polypropylene component of the transponder, initially involving the barbed area and then in some cases extending completely around the entire transponder site." (p. 523) Further, mass development was often observed to begin at the glass-polypropylene interface. (p. 521, Figure 1 caption, reproduced on previous page.)

The mice used in this study were transgenic p53+/- mice, specially bred to lack part of the tumor suppressor gene known as p53. In normal mice, p53 regulates cell growth and causes potentially cancerous cells to destroy themselves. Missing a part of this gene makes mice more susceptible to cancer from genotoxins, or toxic substances that affect genetic material.

The researchers write that "deletion of a single allele of this tumor suppressor gene in mice appears to be without effect on the development of spontaneous tumors, at least during the first year of life, but it imparts exquisite sensitivity to the mutational and carcinogenic effects of genotoxic chemicals." (p. 524) In other words, p53+/- mice do not develop tumors spontaneously in the absence of genotoxins. When they do develop tumors, it is generally an indication that a genotoxin is present.

Because the glass capsule and polypropylene sheath around the microchip implant are not generally considered to be genotoxins, the mice should not have responded to their presence by developing cancers. Researchers did not expect this outcome, writing: "the observation of transponder implantation site sarcomas in 18/177 (10%) of the animals studied was surprising."

Additional Findings

- "Membrane endothelialization, inflammation, mesenchymal basophilia, dysplasia, and sarcoma were considered unequivocal [unmistakable] responses to the transponder" (p. 523)
- The masses increased in size rapidly. One mass measuring ½" wide in the fifteenth week of the study grew to 2" just ten weeks later. (p. 520)
- The researchers "have subsequently replicated this finding in 2 separate studies with the p53+/- mouse where transponder implantation site sarcomas were also observed." Their article does not indicate whether these studies have been published.

Study Details

- The study was conducted by Kerry Blanchard and other researchers¹² at the Department of Toxicology and Safety Assessment at Boehringer Ingelheim Pharmaceuticals in Ridgefield,

¹² Curt Barthel, Henry Holden, Roger Moretz, Franklin Pack, and Raymond Stoll.

Connecticut, along with John French and Raymond Tennant of the Laboratory of Environmental Carcinogenesis at the National Institute of Environmental Health Sciences in North Carolina.

- Animals used were transgenic p53^{+/-} mice, specially bred to lack part of the tumor suppressor gene known as p53. These mice have an increased susceptibility to cancer from genotoxins (compounds which affect genetic material) but are not known to develop tumors spontaneously in the absence of a carcinogen.
 - Microchips used were IMI[®] implants from BioMedic Data Systems. The microchip is described as encased in a glass capsule and partially encased in a polypropylene sheath.
-

Palmer et al., 1998

Fibrosarcomas associated with passive integrated transponder implants. *Toxicologic Pathology*. 1998;26:170.

Author(s)	# of Animals	Species	Study Length	Developed Cancer
Palmer et al., 1998	800	mice	2 years	2.0%

"All tumors were observed . . . at or near the implantation site . . . [the tumors] were attached to the implant or partially or totally encased the implant." (p. 170)

Summary of Study

800 mice were implanted with microchips for identification purposes. After two years 2% of the mice had developed cancerous tumors (malignant fibrosarcomas) around the implants.

Study Design and Key Findings

The article is a short, one-page writeup, around 350 words in length. The following is known based on the information provided:

800 mice were implanted with a microchip transponder for identification purposes as part of "a 104-week dietary study" lasting two years. Between weeks 79 and 105, 16 of the mice developed "subcutaneous tumors associated with the implanted transponder." The tumors occurred in both control and treated animals and were judged unrelated to the test material. The tumors were identified as malignant fibrosarcomas.

All of the tumors occurred at or near the implantation site and were "attached to the implant or partially or totally encased the implant." The larger tumors commonly had areas of necrosis and hemorrhage with inflammation, and some of the tumors invaded adjacent skeletal muscle. In addition, two of the mice developed metastases in which the cancer spread either to the lymph nodes or to the lungs.

Study Details

- The study was conducted by T. Palmer and other researchers¹³ at Covance Laboratories, Inc. in Madison, Wisconsin.
- Animals used were B6C3F1/CrIBR VAF/Plus mice.
- Microchips used were identified as "passive integrated transponder implants used for identification." No additional information is provided.

13 J. Nold, M. Palazzolo, and T. Ryan.

Tillmann et al., 1997

Subcutaneous soft tissue tumours at the site of implanted microchips in mice. *Experimental and Toxicologic Pathology*. 1997;49:197–200.

Author(s)	# of Animals	Species	Study Length	Developed Cancer
Tillmann et al., 1997	4,279	mice	lifespan	0.8%




Fig. 1. Subcutaneous tumour associated with the transponder (size of the microchip 2 × 12 mm).

"The neoplasms induced in the present investigation are clearly due to the implanted microchips." (p. 200)

"Further information on [tumors] induced by microchips, e.g., experiments on their chemical components (glass and polypropylene cap), or the physical presence of the implant alone are necessary." (p. 200)

Summary of Study

4,279 mice were injected with microchip implants for identification purposes. Of these, 36 developed

malignant tumors (fibrosarcoma and malignant fibrous histiocytoma) that were "clearly due to the implanted microchips." (p. 200) Control animals as well as experimental animals developed the tumors.

Study design and key findings

4,279 CBA/J mice were implanted with microchips for identification purposes as part of a study examining the influence of X-ray radiation and chemical carcinogen exposure on offspring. A sample of male mice was exposed to these carcinogens once or twice, then mated with untreated females. Their offspring were then studied to see if they had increased cancer susceptibility.

By the conclusion of the study, 36 of the mice had developed tumors around the microchip. Implant-related tumors were identified as fibrosarcomas with "extensive local invasion of the surrounding tissues" and malignant fibrous histiocytoma with "zones of necrosis and high mitotic activity." (p. 198)

Significantly, twice as many females developed cancers than male mice, though the females had not been exposed to the experimental treatment. 1.2% of the females and 0.5% of the males developed tumors in the chip implantation area. The authors wrote that "the different generation and treatment groups showed no influence on tumour incidence," meaning that the tumors were unrelated to the x-ray treatment or other experimental factors.

The authors caution that the study may have underestimated the actual rate of tumor formation, since only tumors that were visible to the naked eye were examined microscopically. Tumors at an earlier stage of development may have been missed.

Study Details

- The study was conducted by Thomas Tillmann, Kenji Kamino and Ulrich Mohr at the Institute of Experimental Pathology at the Hannover Medical School in Hannover, Germany, and other researchers.¹⁴
 - An acknowledgment at the end of the article states: "This study was supported by the European Union: EV5V-CT92-0222."
 - Animals used in the study were CBA/J mice.
 - The implants used were "glass-sealed devices with a polypropylene cap" obtained from BioMedic Data Systems, Inc. (European distributor PLEXX BV, Elst. The Netherlands).
-

14 Other researchers included C. Daserbrock, H. Ernst, and G. Morawetz of the Fraunhofer Institute of Toxicology and Aerosol Research in Hannover, Germany; E. Campo and A. Cardesa of the Department of Anatomic Pathology at the University of Barcelona in Barcelona, Spain; and L. Tomatis of the Istituto per L'Infanzia in Trieste, Italy.

Johnson, K., 1996

Foreign-body tumorigenesis: Sarcomas induced in mice by subcutaneously implanted transponders. *Toxicologic Pathology*. 1996; 33(5):619. Abstract #198.

Author(s)	# of Animals	Species	Study Length	Developed Cancer
Keith Johnson, 1996	2,000	mice	2 years	~1.0%

"Investigators using . . . implanted devices need to be aware of foreign-body tumorigenesis [cancer development] when evaluating the results of long term studies using mice."

Summary of Study

A two-year Dow Chemical study of 2,000 mice found an approximately 1% incidence of sarcomas surrounding microchip implants used for identification purposes. The tumors appeared in both control and experimental animals. This was consistent with a diagnosis of foreign-body-induced sarcoma.

Study design and key findings

This report was based upon a series of five oncogenicity (cancer) studies involving 2,000 B6C3F1 mice and CD1 ("albino") mice. Each study consisted of 400 mice that had been implanted with a microchip for identification purposes: 300 of the mice received test chemicals in their feed at low, medium, and high dose levels, and 100 control mice received no test chemical. After two years, just under 1% of the mice developed "incidental" subcutaneous sarcomas that incorporated the implanted microchip. Both treated and control animals developed the tumors at approximately the same rate, ruling out the test substance as the cause of these tumors.

The tumors were identified as connective tissue cancers, or fibrosarcomas, and appeared typical of foreign-body-induced sarcomas. The tumors typically appeared after more than one year post-implantation. Only gross lesions were examined.

In a telephone interview, Johnson also reported occasional adverse events related to the microchips, which were implanted between the shoulder blades. "Occasionally some would be inserted too deep, the needle that put them in was probably held at the wrong angle. We had a few early in the studies that would migrate out if the wound wasn't healing properly, and we had a few that gave up functioning, but those were all pretty rare events," he said.¹⁵

Study Details

- The research was conducted at the Toxicology Research Laboratory, The Dow Chemical Company, Midland, MI by Keith Johnson.
- Animals used in the study were B6C3F1 mice and CD1 ("albino") mice.
- Microchip implants were from BioMedic Data Systems Inc.

¹⁵ Keith Johnson, personal communication (telephone interview) October 13, 2007.

**Microchip Studies In Which No Cancer Was Found
(Presented in reverse chronological order)**

Murasugi et al., 2003

Histological reactions to microchip implants in dogs. *The Veterinary Record*. 2003(Sept 13);328.

Author(s)	Species	# of Animals	Length of Microchip Exposure	Developed Cancer
Murasugi et al., 2003	dogs	6	≤ 1 year	none observed
		3	3–6 years	




FIG 2: Cutaneous tissue section 72 months after microchip implantation showing infiltration of the tissue into the space between the cap and the body of the microchip (arrow). Bar=5 mm

"As the mean lifespan of dogs as companion animals increases, long-term evaluation of the safety and biological stability of implants is necessary." (p. 328)

Summary of Study

Nine dogs were implanted with microchips and observed for adverse outcomes over periods of three days to three years. One dog was exposed to the implant for six years. The chips and surrounding tissue were removed and examined microscopically. Inflammation and encapsulation had occurred, but no tumors or cancerous changes were found.

Study Design and Key Findings

Nine dogs (one female beagle, six female crossbreeds, and two male crossbreeds) were implanted with Destron Fearing LifeChip microchips. At selected time periods, the implants and a surrounding 2x2x2 cm cube of tissue were surgically

removed from each dog and microscopically evaluated. The evaluations took place on the following schedule:

# of Dogs Evaluated	Length of Microchip Exposure
2	3 days
2	3 months
2	1 year
2	3 years
1	6 years

After three days, a rim of inflammatory cells, blood congestion, and newly formed capillaries had developed around the implants. At three months, a capsule composed of connective tissue, elastic and collagen fibers had surrounded the implant. At twelve months, the encapsulation was complete and no inflammation was observed. The evaluations at 36 and 72 months were similar to those made at 12 months.

The researchers summarized these findings as follows:

"a foreign body reaction to the subcutaneously implanted microchips was observed [initially] . . . followed by . . . the development of a thin capsule in close contact with the microchip. The inflammatory reactions disappeared three months after implantation, and enclosure of the microchip by a capsule consisting of fibroblasts, collagen fibres and elastic fibres was complete after 12 months. No marked difference was observed . . . 36 or 72 months after implantation, compared with those 12 months after implantation." (p. 329)

The researchers concluded that "These findings suggest that implanted microchips are likely to function safely throughout a dog's lifetime, without causing further histological [microscopic] changes."

Concern over the Statistical Validity of the Study Findings

Although the authors conclude that "implanted microchips are likely to function safely throughout a dog's lifetime," the absence of cancerous changes in a small sample of dogs exposed to microchips for a limited period is not sufficient evidence to conclude that microchip implants are safe for long-term use. Problems with this study include the small number of dogs examined and the short time of their exposure to the microchip.

A small sample size of just nine dogs lacks the statistical power to detect an effect that may be on the order of a percentage point or less. *Statistical validity* is the degree to which an observed result, such as a difference between two measurements, can be relied upon and not attributed to random error in sampling and measurement (National Women's Health Resource Center). *Sample size* is what gives a study statistical power, or accurate and valid predictive ability.

Dr. Elise Whitley and Dr. Jonathan Ball (2002), experts on medical statistics, explain the importance of sample size in medical studies designed to prove the safety of a device and rule out an adverse effect. They write:

"The ideal study for the researcher is one in which the power is high. This means that the study has a high chance of detecting a difference between groups if one exists; consequently, if the study demonstrates no difference between groups the researcher can be reasonably confident in concluding that none exists in reality. The power of a study depends on several factors, but as a general rule higher power is achieved by increasing the sample size.

It is important to be aware of this because all too often studies are reported that are simply too small to have adequate power to detect the hypothesized effect. In other words, even when a difference exists in reality it may be that too few study subjects have been recruited . . . the erroneous conclusion may [then] be drawn that there is no difference between the groups. This phenomenon is well summed up in the phrase, 'absence of evidence is not evidence of absence'. In other words, an apparently null result that shows no difference between groups may simply be due to lack of statistical power, making it extremely unlikely that a true difference will be correctly identified."
[Emphasis added]

Source: Whitley & Ball, "Statistics review 4: Sample size calculations"

In this case the "difference" described is the difference between the rate of cancer formation in dogs that have and have not been microchipped. The present study assumes that the difference between these populations is zero or non-existent, but the sample size lacks the statistical power to state that conclusion.

To determine whether microchips are safe in dogs would require the statistical power of a much larger sample on the order of hundreds or even thousands of dogs.¹⁶

In addition to the small sample size used, a further problem with this study is the short duration of time the dogs were in contact with the implants. Of the nine dogs studied, six had the implant removed within a year or less and only one dog retained the implant for six years. The researchers do not state the age of the dogs at the time they were implanted.

In mouse and rat studies, the onset of microchip-induced cancer typically did not occur until the second year after implantation. Very few tumors were seen in the first year of the study when the animals were in adolescence and early adulthood; most tumors arose during middle age and older for those animals. If dogs develop adverse microchip reactions at a comparable rate, we would not expect to see an onset of tumors in dogs until they, too, reached middle age and beyond. This would correspond to roughly six years of age, given that the average life span of a dog is just over 12 years.¹⁷

The two microchip-induced cancers reported in dogs (Vascellari et al., 2006, 2004) occurred in 9-year-old and 11-year-old dogs after exposure times of seven months and 19 months, respectively. Given the small number of reported cases, it is difficult to draw conclusions about the development of microchip-induced tumors in dogs, but it could be that older dogs are more susceptible to the possible cancer-inducing effects of implants than younger dogs. Future research could help determine the role of an animal's age and the duration of microchip exposure.

Study Details

- The study was conducted by E. Murasugi, H. Koie, M. Okano, T. Watanabe, and R. Asano, of the Department of Veterinary Medicine, College of Bioresource Sciences at Nihon University in Fujisawa, Kanagawa, Japan.
- An acknowledgment at the end of the article states, "We would like to thank Dainippon Pharmaceutical for providing the microchips."
- Microchip implants were described as "LifeChip injector; Destron Fearing. The microchips were approximately 2 mm in diameter and 11 mm long and contained an IC recording a unique identity number. . . [the microchips] are made of biocompatible glass and polypropylene..."

¹⁶ In the recommendation section at the end of the present report, it is proposed that researchers could draw on the existing population of microchipped dogs in the United States to reach more statistically valid conclusions about the implant's safety and long term effects.

¹⁷ The average life span of the domestic dog is 12.8 years, with wide variation across breeds. The average bulldog lives just nine years, while the average chihuahua has a 15 year life expectancy (McCulough, 2007).

Ball et al., 1991

Evaluation of a microchip implant system used for animal identification in rats. *Laboratory Animal Science*. 1991;41(2):185–186.

Author(s)	Species	# of Animals	Length of Microchip Exposure	Developed Cancer
Ball et al., 1991	rats	10	2 weeks	none observed
		10	3 months	
		10	6 months	
		10	1 year	

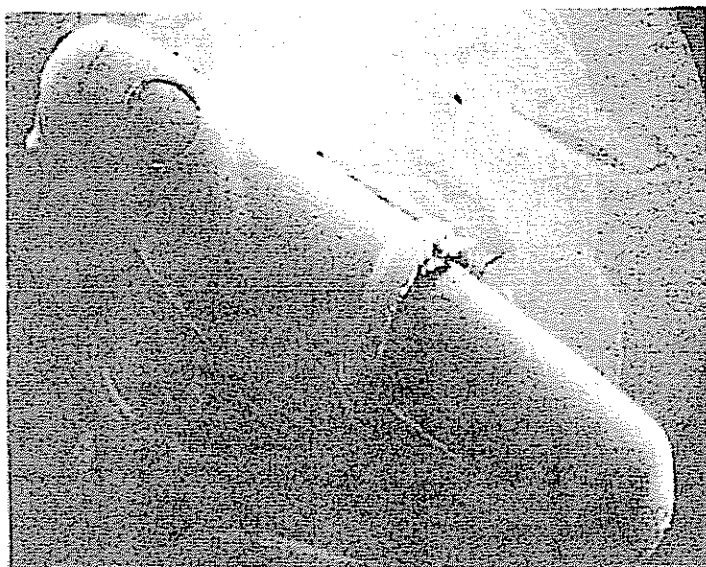

Figure 2. Scanning electron micrograph of IMI transponder 52 weeks postimplantation. The general morphology of both the glass capsule and polypropylene sheath were comparable to transponders before implantation. Higher magnifications revealed comparable results.

Summary of Study

40 rats were implanted with subcutaneous microchips and evaluated for adverse reactions. The tissue surrounding the implants was evaluated after periods ranging from two weeks to one year. No palpable masses or visible tissue reactions were observed.

Study design and key findings

This was one of the original studies undertaken to evaluate what was then referred to as "a new microchip-based animal identification system" being marketed to laboratory researchers by BioMedic Data Systems, Inc. The goal of the study was to evaluate the safety and effectiveness of implanted microchip transponders for laboratory animal identification.

For this study, 20 male and 20 female Sprague-Dawley rats were injected with microchip implants and observed for adverse reactions. At weeks 2, 12, 26, and 52, five rats of each sex were sacrificed (killed). The microchips and surrounding tissue from each rat were examined macroscopically and through histopathologic examination.

Although the researchers reported the development of "thin rims of immature fibrous connective tissue with occasional subacute inflammatory cells present in the subcutis 2 weeks after implantation" (p. 185-186) and later found that "very thin rims of mature fibrous connective tissue were seen surrounding the implant sites" (p. 186) they did not find any cancerous changes. They concluded that the implant was a "reliable, easy-to-use, nonadverse identification system." (p. 186)

Concern over the Design and Statistical Validity of the Study

Although the authors conclude that the implanted transponders "produced no adverse clinical or histopathological side effects in the rats," the findings must be evaluated in light of the short time period the rats were implanted and the small sample size used.

Of the 40 rats used in this early study, none were in contact with the implants for longer than a year. Later researchers, however, found that cancerous tumors generally occur in the second year of exposure.¹⁸ When Elcock et al. (2001) examined a much larger sample of rats (n = 1,040), for example, they found a nearly 1% incidence of microchip-induced cancer, all of which occurred during the second year of the study. The average age of the animals at tumor onset in that study was 585 days, or approximately one year and seven months. Johnson (1996) similarly found that tumors in mice develop during the second year of exposure.

The absence of cancerous tumors in the present study—in which animals were examined after only 2 weeks, 3 months, 6 months, and 1 year of implant exposure—is in accord with the findings of other researchers. It is neither surprising nor anomalous, nor does it rule out the potential that microchip-induced tumors may develop in rats after a longer exposure period.

Another problem with the present study is the small number of animals that were evaluated. A sample size of 40 rats lacks the statistical power to detect a small effect. This was the case in the Murasugi et al. dog study discussed earlier, and the same discussion of sample size and statistical power is applicable.

When Elcock et al. (2001) conducted a subsequent study using a much larger sample of Fischer 344 rats (n = 1,040), they found a nearly 1% incidence of tumor formation. Due to the larger sample size, those results have greater statistical validity than those of the present study.

Study Details

- The study was conducted by D.J. Ball from Boehringer Ingelheim Pharmaceuticals, Inc. in Ridgeford, Connecticut, and associates.¹⁹
- The researchers thanked BioMedic for contributing to the study: "We would like to thank BioMedic Data Systems, Inc. of Maywood, N.J. for the implants and associated electronic equipment..."
- Animals used were Sprague-Dawley rats.
- Microchips used were from BioMedic Data Systems, Inc., Maywood, New Jersey. The chip was described as a miniature transponder hermetically sealed in an inert glass capsule with a polypropylene sheath that covered one end of the transponder.

¹⁸ The only exception in the studies reviewed here was the Blanchard et al. (1999) study in which 10.2% of mice developed cancer within six months of implantation. These findings were atypical, however, and may be attributable to the type of genetically altered mouse used in the Blanchard study.

¹⁹ Additional authors include G. Argentieri, R. Krause, M. Lipinski, and R. I. Robinson from the Sandoz Research Institute of East Hanover, New Jersey; R.E. Stoll from Cetus Corporation of Emeryville, California; and G.E. Visscher from Roche Dermatologics in Nutley, New Jersey.

Rao & Edmondson, 1990

Tissue reaction to an implantable identification device in mice. *Toxicologic Pathology*. 1990;18(3):412–416.

Author(s)	Species	# of Animals	Length of Microchip Exposure	Developed Cancer
Rao & Edmondson, 1990	mice	10	3 months	none observed
		10	15 months	
		74	2 years	
		39	Less than 2 years	

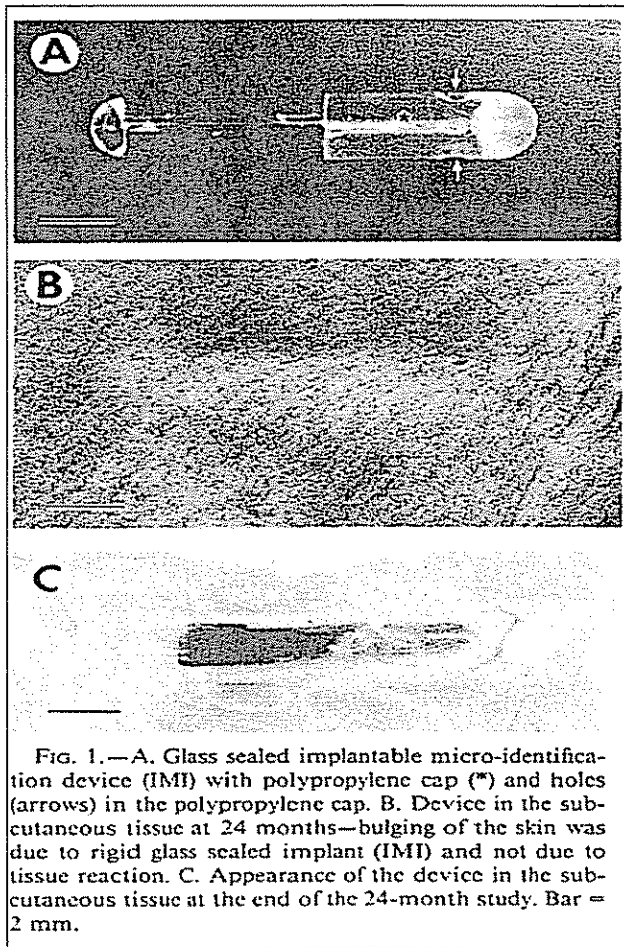


FIG. 1.—A. Glass sealed implantable micro-identification device (IMI) with polypropylene cap (*) and holes (arrows) in the polypropylene cap. B. Device in the subcutaneous tissue at 24 months—bulging of the skin was due to rigid glass sealed implant (IMI) and not due to tissue reaction. C. Appearance of the device in the subcutaneous tissue at the end of the 24-month study. Bar = 2 mm.

Summary of Study

140 mice were implanted with subcutaneous microchips and evaluated for adverse reactions. The tissue surrounding the implants was examined after periods ranging from three months to two years. No neoplastic (abnormal tissue growth) reactions were observed.

Study design and key findings

The study was published in 1990, at a time when implantable microchips were first being introduced to laboratories for animal identification purposes.

The goal of the project was to "determine the tissue reaction [from the implant], especially its potential to cause subcutaneous sarcoma, and the stability and reliability of a glass-sealed permanent identification device" implanted in mice. (p. 412 – 413)

Researchers implanted 140 B6C3F1 mice with a microchip at approximately six weeks of age. Ten mice of each sex were evaluated at 3 months and at 15 months. The remaining animals were evaluated at 24 months.

Histologic examination presented a connective tissue capsule of variable thickness around most of the implants, especially in the area of the glass surface of the chips. Around the polypropylene cap of the transponder, inflammatory reactions were detected but no neoplasms observed.²⁰

20 From a summary of the Rao & Edmondson study included in Tillmann et al. (1996), p. 200.

The following chart shows the length of time each subgroup of mice was exposed to the microchip implant before being evaluated.

# of Mice	Length of Implant Exposure
10	3 months
10	15 months
74	2 years
39 ²¹	Less than 2 years (evaluated prior to study conclusion due to death of the animals)
7	Transponder lost or failed

The capsule that formed around the polypropylene cap of the device contained minimal to mild inflammatory reaction with lymphocytes, macrophages, and a few plasma cells and neutrophils. "Chronic granulomatous inflammation . . . was also observed around the polypropylene cap of 2 implants." (p. 414)

Though no cancer was found, there were other problems with the implants. According the researchers, two of the implants were "lost" and four of the devices "failed." Three of these failures were attributed to microscopic cracks in the weld connecting the antenna leads to the microchip, and one was caused by "leakage of the glass capsule resulting in fluid accumulation around the microchip." (p. 413) One device lodged in the subcutaneous tissue over the lumbar vertebrae and was pushed out slowly through the scar tissue of the injection site during the tenth month of the study.

In addition to the lost or failed transponders, seven of the transponders were discovered in the abdominal cavity of the animals rather than in the subcutaneous tissue where they should have been located. Researchers did not know whether the devices had migrated into the abdominal cavity and eventually fixed in the perirenal tissue, or whether lab technicians had accidentally injected the devices into the abdomen.

Concern over the Design and Statistical Validity of the Study

Given the small sample of animals exposed to the microchip for a full two years, this study may suffer from similar statistical validity problems as the Murasugi et al. (2003) and Ball et al. (1991) studies discussed above.

Tillmann et al. (1997) point out this deficiency in their writeup, stating that the lack of tumor findings by Rao and Edmondson could be explained "by the low number of 140 B6C3F1 mice used by Rao and Edmondson." (p. 200).

Study Details

- The study was conducted by Ghanta Rao and Jennifer Edmondson at the Division of Toxicology Research and Testing at the National Institute of Environmental Health Sciences National Toxicology Program in North Carolina.

²¹ This figure is inferred from the following statements: "Survival at the end of the 24-month study was 74% and 70% for the male and female mice respectively" (p. 413) and "Mice that died during the course of the study...were necropsied...and evaluated by light microscopy for tissue reaction around the device." (p. 413)

- Animals used were B6C3F1 mice.
 - Microchips used were obtained from BioMedic Data Systems, Inc. They were described as "a glass sealed 12 x 2 mm cylindrical device with a snug-fit biocompatible polypropylene cap covering a 5 mm length of the device. There are two holes in the polypropylene cap. The purpose of the polypropylene cap is to elicit mild tissue reaction and immobilize the device at the site of the implantation." (p. 413).
-

Discussion, Recommendations, and Conclusion

Discussion

Cancerous tumors formed around or adjacent to implanted microchips in eight of the 11 studies reviewed in this report. In six of those studies, researchers clearly identified a causal link between the implanted microchip transponder and cancer. In three studies where cancer was not found, methodological shortcomings undermined the studies' validity. Either too few animals were studied to draw a valid conclusion, or the animals were not in contact with the microchip long enough for tumors to develop, in the way predicted by other models.

The tumors generally occurred in the second year of the studies, after more than one year of exposure to the implant. At the typical time of tumor onset the animals were in middle to advancing age. The exception to this was the Blanchard (1999) study, in which genetically modified mice developed fast-growing cancers well before six months.

In almost all cases, the tumors arose at the site of the implants and grew to surround and fully encase the devices. In several cases the tumors also metastasized to other parts of the animals, including the lungs, liver, stomach, pancreas, thymus, heart, spleen, lymph nodes, and musculature.

In addition to the tumors, researchers described other adverse reactions stemming from the use of the microchips, including migration, incorrect insertion, failure, and loss. These adverse reports appeared in studies which did and which did not find cancer.

Issues related to the studies, including several proposed explanations for the cancer findings, the breed and species of animals used, the relevance of this research to implanted microchips in human beings, other adverse reactions reported in the studies, and the possible under-reporting of cancer and other adverse events are discussed in detail below.

Explanations for the Tumors

At the present time, there is no definitive, universally accepted explanation for the formation of malignant tumors around implanted microchips in mice, rats, and dogs. The following are among some of the explanations that have been proposed:

- (1) **Foreign-Body Tumorigenesis:** The presence of the microchip, a subcutaneous foreign body, may cause cellular changes that can lead to cancer.
- (2) **Post-Injection Sarcoma:** Inflammation from the chip-injection procedure may cause cellular changes that can lead to cancer.
- (3) **Possible Genotoxic Properties of the Implant:** The glass capsule or polypropylene sheath surrounding it may have carcinogenic or genotoxic properties, or its presence within the host may give rise to genotoxic byproducts.
- (4) **Radio-Frequency Energy Emissions from the Transponder or Reader:** The radio-frequency energy involved with the transponder may somehow contribute to tumor formation.

Each hypothesis is addressed in this section.

Foreign-body tumorigenesis

It is known that implanted foreign bodies can cause cancer both in animals and humans. McCarthy et

al. (1996) reported on a liposarcoma in a dog where a glass foreign body had lodged 10 years previously. Brand and colleagues (1975) observed that rodents are particularly susceptible to developing tumors in response to foreign bodies and produced a large body of research on the topic. Compelling evidence indicates that foreign-body tumorigenesis is also operative in humans (Jennings et al., 1988), as discussed later in this paper.

Foreign-body-induced tumors can pose serious threats to animal health. Elcock et al. (2001) report from their review of the literature that most tumors arising from foreign bodies are malignant mesenchymal neoplasms with a rapid growth rate, killing the animal in a matter of weeks. (p. 491)

Brand's research revealed that the size and surface of the foreign body are the key characteristics affecting tumor development. Although it may seem counter-intuitive, prior research shows that foreign bodies with smooth, continuous surfaces are actually more carcinogenic than those with rough, scratched, or porous surfaces.

The surface of the foreign body determines, in part, the length of the period of active inflammation. Rough, irregular surfaces have a longer active inflammatory phase before the foreign body is encapsulated in fibrous tissue. The extended period of inflammation is associated with lower rates of tumor development. In contrast, smooth surfaces have a shorter inflammatory period and thus are more likely to lead to tumors. (Elcock et al., 2001, p. 490)

The microchip implant has both a smooth, homogeneous surface in the glass capsule and a rougher portion coated in the polypropylene sheath that is "characterized by scratches, ridges, and other irregularities." (Ball et al.)²²

In relation to the microchip implant, Elcock et al. write: "A chronic foreign body such as the electronic microchip, surrounded by a rim of mature fibrous connective tissue with little or no active inflammation may . . . be more tumorigenic than one with ongoing active inflammation." (p. 490)

On the basis of these prior observations from the literature, it might be predicted that the cancer would form around the smooth portion of the implant first. However, Blanchard et al. (1999) reported that tumors in their study arose at the microchip's "plastic anchoring barb" and then expanded to eventually surround the rest of the device. They write: "It appeared that tumor(s) arose in the mesenchymal tissue surrounding the polypropylene component of the transponder, initially involving the barbed area and then in some cases extending completely around the entire transponder site." (p. 523) Further study is needed to better understand this issue.

Post-Injection Sarcoma

"[I]rritation, inflammation, and/or wounds [promote] tumor development. Virtually anything that causes a local inflammatory reaction may potentially be responsible for neoplastic [cancer] initiation."

—Vascellari et al., 2006 (p. 546)

The microchip implant procedure involves the insertion of a 12-gauge needle into an animal's flesh to deliver the device. That procedure alone may be problematic, as research indicates that inflammation resulting from injections can predispose tissues to developing cancer. The resulting malignancies are known in the veterinary literature as *post-injection sarcomas*.

²² Ball's team wrote: "The glass capsule had a smooth, homogeneous surface. The polypropylene sheath that covered one end of the transponder had a manufactured hole at its closed end. Its surface was characterized by scratches, ridges, and other irregularities." (p. 186)

Vascellari et al. (2006) suggest that the tumor they evaluated in a French bulldog may have been this type of post-injection sarcoma, caused either by the injection of the microchip or by injection of vaccines that the dog received at the same site.

In light of the potential for post-injection sarcomas to develop in dogs, it would seem prudent to reduce inflammatory injection reactions in dogs (and cats) as much as possible. Given these findings, veterinarians should identify the location of microchip implants in chipped animals and avoid using the same site for vaccinations or other injections.

Possible Genotoxic Properties of the Implant

In the Blanchard study over 10% of p53^{+/-} mice developed malignancies around the implants. This finding puzzled the researchers, as the mice they used were genetically modified to develop tumors specifically in response to mutagens and genotoxins (toxic substances that affect genetic material). However, the component materials of the transponders are "widely used in genotoxicity studies" and are not known to be mutagens or genotoxins.

This discrepancy suggested to the researchers that something other than a foreign-body reaction or an injection response may be involved in the microchip-induced cancers they found. The researchers suggest that "the presence of the foreign body may elicit tissue reactions capable of generating genotoxic byproducts." They provide technical descriptions of several processes through which this may occur on page 526 of their study.

It is unclear whether the suspected genotoxic byproducts were produced by the implant directly or through processes occurring in the surrounding tissues of the host animals – or a combination of the two. The mice used in the Blanchard study were genetically modified to lack a portion of the p53 gene that normally aids in the repair of damaged cells. The higher rate of malignancy seen in these animals may result from their inability to repair cellular damage resulting from the implant.

The Blanchard report does not evaluate the biocompatibility of the polypropylene polymer sheath, but it does note that the observed tumors arose in the tissue surrounding the polypropylene component of the transponder. (As noted above, the tumors began at the microchip's plastic anchoring barb and expanded to eventually surround the rest of the device.) This suggests another possibility: that "leachates," or substances leaching from the implant into the surrounding tissue, may be involved in the tumorigenesis. (Blanchard, et al., p. 525)

A literature review to assess the safety of the polymer sheath was beyond the scope of this report but would contribute to a fuller discussion of microchip-induced tumors.

Radio-Frequency Energy Emissions from the Transponder or Reader

Blanchard et al. also raised the possibility that "energy from the signal transmitted by the transponder [may be] carcinogenic" (p. 525) Though there is a tendency to think of the glass encapsulated transponders as biologically inert, the reality is that these implants are radio-frequency energy transponders designed to pick up and amplify electromagnetic radiation (EMF) within the body. The long-term effects of having a reactive, foreign-body capsule in the body designed to absorb and respond to electromagnetic energy are unknown.

Based on a review of published accounts, it appears the role that EMF radiation may play in the development of microchip-induced tumors has not been well studied. Blanchard et al. believe that "these variables warrant further examination." (p. 525)

Differences between Species

An important factor to consider when interpreting animal studies is whether findings in one breed or species of animal are applicable to other animals or to humans. This section examines that issue.

Possible Difference in Tumor Susceptibility Between Different Strains of Mice

In studies where microchip-induced malignant tumors were found, the percent of mice affected ranged from a low of 0.8% in the CBA/J mouse to a high of 10.2% in the p53+/- mouse. This wide variation suggests that different strains of mice may have different degrees of susceptibility to cancer from the implants.

Le Calvez et al. (2006), Palmer et al. (1998), and Elcock et al (2001) all suggest a strain difference, with Palmer and Elcock observing that no implant-induced sarcomas have been reported in the CD-1 mouse strain, for example.²³ However, Johnson (1996), whose study of both B6C3F1 mice and CD1 mice found a ~1% overall incidence of microchip-induced tumors, believes that CD1 mice in his study "probably did" develop foreign-body sarcomas around the implanted microchips.²⁴ Nonetheless, it appears that different strains of mice may develop microchip-induced cancers at differing rates.

Tumor Susceptibility across Species

It has long been observed that different species have differing levels of susceptibility to foreign-body tumors. As reported in Rao and Edmondson (1990), evaluation of prior research shows that mice, rats, and to some extent, dogs are more susceptible to foreign body tumorigenesis than guinea pigs, chickens, and hamsters, for instance.²⁵

The fact that rodents and dogs have developed cancer in response to implants does not necessarily mean that humans will do the same. Blanchard et al. caution that "blind leaps from the detection of tumors to the prediction of human health risk should be avoided." (p. 526) In humans, fibrotic scar formation proceeds at a much slower rate than in rodents, which might indicate that humans are more resistant to foreign-body-induced tumors than rats and mice, suggest Elcock et al. (p. 491)

Humans are Susceptible to Foreign-Body Carcinogenesis

Nevertheless, according to Elcock's summary of the literature on foreign-body tumorigenesis, any inert substance inserted into the body for long periods can produce neoplasia (abnormal tissue growth), including in humans. (p. 489) Vascellari et al. (2004) note that foreign-body-induced sarcomas, including osteosarcomas, rhabdomyosarcomas, haemangiosarcomas, and liposarcomas, have been described in humans, although with a low prevalence. (p. 190)

Most of the malignant, microchip-induced tumors in rodents reviewed in the present report were classified as sarcomas – soft tissue cancers that afflict the muscles, tendons, fibrous tissues, fat, blood vessels, and nerves. The following is a brief description of this type of cancer in human beings from Blake Morrison (2003) of Baylor University Medical Center:

23 Elcock et al. suggest that cancer may be difficult to rule out even in CD-1 mice, however, since "small pre-neoplastic or neoplastic lesions may have been missed" in the absence of microscopic evaluation. (Elcock et al., p.489)

24 Johnson stated in a 2007 email correspondence: "I do not specifically recall whether or not CD-1 mice developed foreign-body sarcomas around implanted microchips. I believe they probably did, but at slightly lower incidence than B6C3F1 mice, as our experience was that CD-1 mice were somewhat shorter lived (due a disease named systemic amyloidosis) and these tumors were generally seen after a long time on study." (Personal communication, October 15, 2007.)

25 Citing Brand, KG, 1982.

"Soft tissue sarcomas are a diverse group of neoplasms that arise in the connective tissues throughout the body. They account for approximately 1% of adult malignancies and 7% to 15% of pediatric malignancies. About 50% to 60% of sarcomas occur in the extremities [the arms and legs], and although they are rare, they are responsible for more deaths than testicular cancer, Hodgkin's disease, and thyroid cancer combined. These tumors are notorious for recurring and metastasizing—often with devastating results—despite apparently complete resection....The National Cancer Institute's Cancer Surveillance, Epidemiology, and End-Result (SEER) Program in 1996 reported 6400 new cases of soft tissue sarcoma, including 3500 in males and 2900 in females (2), for a male-to-female ratio of about 1.2:1."

Sarcomas can arise in human beings in scar tissue as a result of "foreign body implantation" among other causes, according to Kasper et al. (2004).

Jennings et al. (1988) reviewed published research involving six cases of angiosarcoma and 40 cases of sarcomas of other types associated with foreign-body material in humans. They found that these cases "provide compelling evidence that solid-state [foreign-body] tumorigenesis is operative in humans," and note that "implanted foreign material...should be considered capable of inducing virtually any form of sarcoma in humans" (Jennings et al., 1988).

Jennings et al. describe each of the three cases investigated in their study as "a high-grade tumor, which metastasized and led to the death of the patient." (p. 2443) In commenting on cases from the prior literature, they observe that the malignancies developed between four months and 63 years after exposure to the foreign body, and that the foreign-body related sarcomas "appear to be highly aggressive, both morphologically and biologically." (p. 2443)

Other researchers have also found highly aggressive sarcomas and carcinomas developing in humans around or near implants, including pacemakers, (Biran et al., 2006; Rothenberger-Janzen et al., 1998; Rasmussen et al., 1985), vagus nerve stimulators (Cascino et al., 2007), and orthopedic implants (Keel et al., 2001). Based on these findings, researchers recommend that all material near implants that is removed from patients should be carefully examined for cancerous changes.

In another case, surgical threads found within and near a malignant tumor were believed to have induced tumorigenesis (Martin-Negrier et al., 1996). The researchers cite Brand's animal studies showing that the physical presence and not the chemical components of the implant of foreign bodies may be responsible for tumorigenesis, and point out that the most critical factor in the induction of these sarcomas is the formation of a fibrous capsule around the foreign body. They note that, "in our case the persistence of a foreign body...and the presence of large extensive fibrosis areas in the tumor seem to be in agreement with this possibility."

Brand et al., (1975) reporting on rodent studies, note that removing the foreign body may not be enough to prevent the development of cancer once the tumorigenesis process is already underway. They write:

"As reported in the literature and infrequently observed in our laboratory, removal of the [foreign body] implant from the tissue capsule during the late preneoplastic period does not always abort development of tumors from the remaining empty capsule. . . . However, removal of the [foreign body] left a solid collagenous, possibly even calcifying or ossifying, scar that failed to resolve and therefore acted like [foreign body] material. The latter explanation may underline the occurrence of scar-related sarcomas in man, as reported in the literature." (p. 283)

Other Adverse Reactions to the Implants

Several studies incidentally reported other problems related to the microchips, including migration (shifting location in the body), incorrect insertion, failure to work, and loss from the body.

Migration

Despite the presence of the polypropylene sheath designed to anchor the implanted microchip, chip migration appears to be an ongoing problem. Le Calvez et al. found that microchips that had migrated from the initial implantation site accounted for 19.3% of the tumors they observed. Although the devices were originally injected into the backs of the animals, the microchip-associated tumors were later found in the limbs (4/52), the abdominal region (4/52), and the dorsal head (1/52). (p. 259)

Murasugi et al. reported no cases of migration in their study of nine dogs. However, Jansen et al. (1999) found that about half of the transponders inserted into the shoulders of beagle dogs in a four-month study had migrated to some extent. Reports from veterinarians also indicate that migration is a problem in dogs. In the United Kingdom, a voluntary registry of adverse reactions to microchip implants has been maintained by the British Small Animal Veterinary Association (BSAVA) for several years. Migration is the most common problem reported to the BSAVA, with "the elbow and shoulder being the favourite locations of wayward microchips" (BSAVA, 2004). The BSAVA reports that "It is surprising how quickly some microchips migrate," noting that microchips have been found in a different location as little as one week after implantation or up to ten years later (BSAVA, 2003). Over 180 cases of migration have been reported to the BSAVA since 1996.

Injection Error

Occasionally, due to technician error, implants are injected into the wrong site on animals. Rao and Edmondson reported that 5% (7 of 140) of the microchips used in their study were later found in the perirenal area (in the abdominal cavity, surrounding the kidneys) instead of in the correct implant area just under the skin on the back. They surmise that the implants either had migrated or had been injected incorrectly directly into the abdomen. Johnson reported similar problems, stating, "occasionally some would be inserted too deep, the needle that put them in was probably held at the wrong angle" (Johnson, personal communication, 2007).

Like migration, the danger of incorrect injection also poses a risk to pets. The BSAVA cautions that technicians must be properly trained to perform the implant procedure, citing a "disastrous" incident in 2004 where an attempt to implant a struggling kitten resulted in its sudden death. A post-mortem examination later revealed that the microchip had been accidentally inserted into the kitten's brainstem (BSAVA, 2004). In another case a cat suffered severe neurological damage when a microchip was accidentally injected into its spinal column (Platt et al., 2006).

Failure and Loss of Transponder

Other problems with the microchips include failure to function, in which the microchip ceases to respond to a query from the reader device, and loss, where the microchip exits the body. Rao and Edmondson reported that four of the 140 implants used in their study failed due to microscopic cracks in the weld connecting the antenna leads to the microchip or leakage of the glass capsule resulting in fluid accumulation around the microchip. (p. 413)

Rao and Edmondson also reported that an additional two of the 140 microchips in their study were lost, including one microchip lodged in the subcutaneous tissue over the lumbar vertebrae that was pushed out slowly through the scar tissue of the injection site during the tenth month after implantation.

In the Tillmann study, 1.5% of 4,279 (approximately 64) implanted microchips had to be substituted with new transponders when they either ceased functioning or were lost from the body and later found in the softwood of the cages. Most of the losses occurred in the first two days after implantation, but some occurred as long as seven months later.

Johnson also reported that failure and loss was an issue with the implants, stating: "We had a few early in the studies that would migrate out if the wound wasn't healing properly" (Johnson, personal communication, 2007).

Adverse Reactions Likely Under-Reported

It is likely that the true rate of microchip adverse reactions in the studies was higher than reported, since the purpose of the articles was to discuss microchip-induced cancer, not other complications. One indication that this may be the case is Johnson's personal communication (2007) reporting failure, loss, and migration, as discussed above. Though these events did occur, they were not reported in his original published report and were only solicited in response to a specific query. It is possible that other investigators may have likewise neglected to mention such reactions when they did occur.

Adverse reactions to microchips implanted in dogs and cats may also be substantially underreported. The BSAVA (2003) reported that "2003 saw a marked increase in the number of reports received through the Adverse Reaction Reporting Scheme. It is significant that several reports were received from some quite small practices while many larger practices filed no reports at all. This suggests that there is an element of under reporting which may be happening for a variety of reasons."

Anecdotal evidence supports the proposition that adverse reactions are underreported in the veterinary and oncological literature. A review of Internet discussion boards reveals the following posts by dog owners who believe their pets have suffered adverse reactions from implants (Dogster's, 2007):

My mothers dog "Buddy" actually lost his life to a "large" malignant sarcoma that was located on his back by the chip. It was removed once, but aggressively grew back and quickly took his life. I strongly believe this Chip is what took his life.

My cocker spaniel, Cooper. . .has two microchips in him. The first one quit working, so he was implanted with a second one.

My dogs problem with microchip - swelling area around microchip, even to about 4 cm big, it goes away after a course of AB.

Jack was microchipped at his first vet visit when we got him - oh so many years ago. . . I'm wondering - now that he is a senior citizen, I feel a small lump where the microchip was implanted - I am assuming it's only scar tissue and my vet has backed that up. . .

...when Myrl was microchipped, the vet was very rough and he bled a LOT. She kind of stabbed him with the injector and he yelped and his white fur turned red. It was horrible.

None of these incidents appears to have been formally reported to any agency or decision-making body, and a review of the literature indicates that none has been investigated or written up by the

academic veterinary community. Similarly, although reports of chip-related neurological damage and infection in horses have begun to appear on the Internet,²⁶ few, if any, reports of adverse microchip reactions in horses have been written up in the literature.

Even when pet owners contact veterinarians and researchers to report their adverse experiences, they often find it difficult to get a response. Jeanne, the owner of Leon, the bulldog whose chip-related tumor is described by Vascellari et al. (2006), reports her frustration at how difficult it was to get anyone to pay attention to what had happened. Her quest to tell Leon's story became almost a full-time endeavor as she searched the globe for a veterinary oncologist willing to look at the evidence and investigate the tumor. (McIntyre, 2007; "Jeanne," personal communication, September 2007).

It is clear that a better mechanism for reporting adverse effects is needed and that veterinary oncologists and others need to open a better dialog with members of the public around these important issues.

What Do These Findings Mean for People?

As discussed previously, it is known that humans are susceptible to foreign-body carcinogenesis, though they appear to be less susceptible than rodents. As a foreign body, the microchip implant could potentially give rise to tumors within human beings.

The long-term effects of implanted microchips in human beings are presently unknown. Most human microchips have been implanted since the VeriChip implant received FDA approval for use as a medical device in October 2004. With only 3–6 years of data available on a very small number of people,²⁷ it is difficult to draw definitive conclusions about the safety of the device. If humans follow a similar pattern of microchip-induced cancer development as that observed in mice and rats, we would not expect to see implant-induced malignancies until half a lifetime's exposure, or approximately 30-40 years.

This researcher is aware of no formal follow-up procedure to evaluate the health effects or long-term safety of implanted microchips in human patients. The lack of a formal evaluation procedure and a means of publicly reporting adverse reactions that is well-understood by patients and other implantees means that such reactions could be occurring and yet be unreported to the public or to the FDA.

There is a further consideration in this day of increasing carcinogen exposure. Recent research indicates that exposure to multiple carcinogens, even within safe levels, can result in cancer development at rates that exceed what would be expected from the individual carcinogens alone. This has been called the "toxic cocktail" effect.²⁸

The microchip-induced tumors observed in the Elcock et al. study described in this paper may have been an example of this effect. In that study, only rats exposed to a test chemical developed malignant tumors around the microchips. However, even rats exposed to a very low dose of the chemical compound developed the malignancies. It may be that the microchip, when combined with even small doses of a chemical compound, worked together to bring about a cancerous response.

It is estimated that every day we are exposed to 75,000 artificial chemicals (Trivedi, 2007). It would therefore seem prudent to avoid unnecessary or elective exposure to additional potential cancer-causing agents – such as implanted foreign bodies – either in ourselves or in our pets.

26 See, for example, Dutch Group Nijhof.

27 The VeriChip Corporation has reported that approximately 300 people in the United States and 2,000 people worldwide have been implanted with their product.

28 For a discussion of research regarding this effect see Trivedi, 2007.

Recommendations

The following recommendations are proposed for physicians, policy-makers, veterinarians, pet owners, and veterinary researchers in light of research findings on microchip implants.

For Implanted Human Patients and Their Doctors

There are many unanswered questions about the safety of microchip implants in human beings, but what we know from animal studies is disquieting. In light of the fact that microchip implants cause serious adverse reactions in animals, the practice of chipping human beings should be immediately discontinued until the tumorigenesis process is more fully understood.

In addition, all patients, members of the public, and medical volunteers who have been implanted with microchips to date (an estimated 300 people in the United States and 2,000 people worldwide) should be immediately informed in writing of the causal link between microchips and cancer in rodents and dogs. Implanted individuals should be offered a procedure for microchip removal at the expense of the facility that provided the implant, should they choose to have the device removed. Following the advice of Jennings et al., the tissue surrounding all removed implants should be histologically examined.²⁹

Physicians whose patients chose to retain the microchips should routinely examine the tissue surrounding the implant for swelling, inflammation, evidence of chip migration, and pain. Any unusual sensations, lumps, or other abnormalities should be analyzed for cancerous or pre-cancerous changes. All adverse reactions, whether related to cancer or other problems, should be immediately reported to the FDA for disclosure in the public record.

For Policy-Makers

Given the clear, causal link between microchip implantation and malignant tumors in laboratory rodents and dogs, it is strongly recommended that policy makers reverse all policies that mandate the microchipping of animals under their jurisdiction or control. These include ordinances passed by state and local authorities, policies implemented at animal shelters, and formal positions adopted by animal welfare, affinity, and interest groups across the United States and around the globe.

It is the opinion of this researcher that mandatory microchipping ordinances should be repealed and replaced with a voluntary system of microchipping at the discretion of pet owners. Any pet owner who chooses to have a microchip implanted in his or her animal should be fully informed of the potential risks of the procedure. No one should be forced by law or otherwise coerced into implanting an animal against his or her conscience or medical judgment.

For Veterinarians

Veterinary offices are one of the most common places where implant procedures are performed. Since veterinarians are often the primary point of contact for pet owners on the topic of microchipping, veterinarians should familiarize themselves with the research findings and carefully consider the potential for adverse reactions before recommending implants for their patients.

Pet owners should be clearly advised of the research linking the microchip to cancer in rodents and dogs when seeking advice about the chipping procedure or choosing to have it done to their pets.

In the case of animals that have already been implanted, Vascellari et al. suggest that veterinary

²⁹ "All material removed from patients in proximity to foreign implants should be examined histologically."
(Jennings et al., 1988, p. 2444)

surgeons should routinely palpate the tissue surrounding microchip implants as part of routine medical care. Any lumps or inflammation should be investigated for cancerous or pre-cancerous changes. To avoid the complicating risk of injection-related sarcoma, veterinarians should avoid administering vaccines or other injections at or near the site of an implanted microchip.

Finally, veterinarians should advise pet owners to routinely examine the site of the implanted microchip themselves and immediately report any abnormalities.

For Pet Owners

There have been no large-scale, statistically valid, clinically controlled, experimental studies involving microchip implants in dogs and cats, so we know very little about their long-term safety. However, the fact that we have not seen an epidemic of cancers in pets would suggest that only a small number will be impacted. As the chip-removal procedure is likely to be both costly and invasive, pet owners may wish to leave the implanted microchips intact within their animals unless a problem surfaces.

Owners of pets that have been implanted should regularly check the area for any abnormal lumps or swelling. If something unusual is found, it should be reported immediately to a veterinarian, and tests should be done to rule out cancer. The pet owner may be the key to detecting a problem in the early stages and saving the life of a pet. In the two cases where dogs developed tumors around and attached to implants, it was the owners' astute eye and probing fingers that found it, not the veterinarian. The only indication that there was a problem was the lump; all other laboratory tests came back within normal ranges.

If a pet is not currently microchipped, it may be best to keep it that way. It is the opinion of this researcher that all further implantation of pets should be halted until the existing population of chipped dogs is carefully assessed for adverse reactions, including cancer. There are other ways to ensure a pet is returned to its owner in the event it goes missing. A well-made collar and a clear, legible tag with the owner's contact information are effective tools that have worked for generations of pet owners.

For Veterinary Oncology Researchers

There is fertile ground for additional research in this area. Indeed, systematic study would add greatly to our understanding of the process of tumorigenesis as related to microchip implants. Other than preliminary research involving very small number of animals (e.g., Ball et al.; Rao and Edmondson), there have been no studies to date that have systematically examined the development of microchip-induced sarcomas as a research goal in itself. Almost all of the cancers reported herein arose incidentally, in the course of other research.

One important direction for future research would be to explore the role of the electromagnetic energy received and transmitted by the transponder. This could help isolate whether the tumors stem from a foreign-body reaction to the external surface of the microchip alone (i.e. glass capsule and polypropylene sheath) or whether some characteristic of the device in its capacity as a radio-frequency transponder could be partially or fully responsible for the tumors. A study could be designed to investigate the role of radio-frequency energy by implanting some animals with intact transponder devices and others with empty capsules, or capsules filled with an inert substance of the same mass as the current contents of the glass capsule. In each of these groups, animals could be exposed to different levels of energy from the reader, as well.³⁰

30 Although these studies would answer several questions raised, for ethical reasons the author does not endorse the use of animals for this type of experimentation.

Proposal to Create a National Registry

The research community and society at large should take advantage of the fact that there are already millions of chipped dogs in the U.S. Rather than conducting further, potentially painful and invasive studies on dogs and other animals, we can use the animals that are already chipped to learn more about how living creatures respond to these devices.

Doing so would require the creation of a central registry for reporting adverse reactions to microchips, including cancer. A registry could be created in one of the following ways:

- Dogs undergoing treatment for cancer could be voluntarily reported to an independent registry set up for this purpose.³¹ Because microchip-induced cancer may metastasize and lead to cancer in other parts of the body, it is important to rule out the microchip as the source of cancer in dogs. Veterinarians would report the chip status of all dogs with cancer under their care, and a statistical analysis could be made to determine whether chipped dogs have a higher overall incidence of cancer than their non-chipped counterparts.
- On a voluntary basis, veterinarians disposing of the remains of chipped animals could remove the microchip and surrounding tissue and send it to a laboratory for histological analysis.

Done on a large scale, these measures would provide important data that could be used to assess the safety of microchip implants in dogs. Establishing national registries for adverse reactions and evaluation of tissue samples would provide a more systematic way of assessing the risk than the current state of relying on case-by-case, anecdotal reports alone.

Conclusion

The body of research reviewed in this report indicates a clear causal link between microchip implants and cancer in mice and rats. It also appears that microchips can cause cancer in dogs—and that they have done so in at least one case, and quite likely in two. These findings raise a red flag about the continued use of microchips in both animals and human beings.

As the Associated Press reported, this concern is shared by some of the nation's most respected cancer researchers.

"There's no way in the world, having read this information, that I would have one of those chips implanted in my skin, or in one of my family members," said Dr. Robert Benezra, head of the Cancer Biology Genetics Program at the Memorial Sloan-Kettering Cancer Center in New York. He added, "Given the preliminary animal data, it looks to me that there's definitely cause for concern."

Dr. George Demetri, director of the Center for Sarcoma and Bone Oncology at the Dana-Farber Cancer Institute in Boston, agreed. Even though the tumor incidences were "reasonably small," in his view, the research underscored "certainly real risks" in RFID implants, adding that the tumors can be "incredibly aggressive and can kill people in three to six months."

Dr. Chand Khanna, a veterinary oncologist at the National Cancer Institute, said that the evidence "does suggest some reason to be concerned about tumor formations." All of the cancer specialists agreed the animal study findings should be disclosed to anyone considering a chip implant.

On the basis of these findings, physicians, patients, veterinarians, and pet owners may wish to

³¹ This could be done through a form similar to that used by the British Small Animal Veterinary Association. Their 2-page "Microchip Adverse Reactions Reporting Form" can be found at http://www.bsava.com/VirtualContent/85185/adverse_reaction.pdf.

carefully consider whether the benefits of implants are worth the potential health risks such implants appear to pose. It is the opinion of this researcher that further microchipping of pets or human beings should be immediately discontinued.

Glossary of Medical Terms

Cancer-related Definitions from the Centre for Cancer Education, University of Newcastle upon Tyne, UK³² and Dorland's Illustrated Medical Dictionary.³³

Adenocarcinoma: A form of cancer that involves cells from the lining of the walls of many different organs of the body. Breast cancer is a type of adenocarcinoma.

Anaplasia: Characteristics of a cell (structure and orientation) that make it identifiable as a cancer cell and malignant.

Angiosarcoma: A malignant tumor originating from blood vessels.

Cancer: A general term for more than 100 diseases that are characterized by uncontrolled, abnormal growth of cells. Cancer cells can spread locally or through the bloodstream and lymphatic system to other parts of the body. (See also: **malignant**)

Carcinogen: An agent capable of initiating the development of malignant (cancerous) tumors. May be a chemical, a form of electromagnetic radiation or an inert solid body.

Carcinogenicity: The tumor-producing/cancer cell-producing potency of an agent.

Fibroblast: Resident cell of connective tissue.

Fibrosarcoma: Malignant tumor derived from connective tissue cells.

Foreign Body: Anything in the tissues or cavities of the body that has been introduced there from without, and that is not rapidly absorbable.

Genotoxin: A toxin (poisonous substance) which harms the body by damaging DNA molecules, causing mutations, tumors, or neoplasms. A substance that can mutate and damage genetic material. (Also *genotoxicant*).

Histiocyte: Long-lived resident macrophage (immune-related cells) found within tissues.

Histiocytoma: A tumor composed of histiocytes.

Histochemical: Study of the chemical composition of tissues by means of specific staining reactions.

Histology: The study of cells and tissue on the microscopic level.

Histopathology: The science concerned with the study of microscopic changes in diseased tissues.

Immunohistochemistry: Histochemical localization of immunoreactive substances using labelled antibodies as reagents.

Induce: To bring on; to effect; to cause.

32 Online at: <http://cancerweb.ncl.ac.uk/omd/index.htm>

33 Online at: www.mercksource.com/pp/us/cns/cns_hi_dorlands.jsp?pg=/pp/us/common/dorlands/dorland/dmd_a_b_00.htm

Inert: Refers to a substance which will not chemically react with anything under normal circumstances.

Leiomyosarcoma: A malignant tumor of smooth muscle origin.

Liposarcoma: A malignant tumor that may be composed of fat cells.

Macrophage: Relatively long lived phagocytic cell of mammalian tissues. In response to foreign materials may become stimulated or activated. Macrophages play an important role in killing of some bacteria, protozoa and tumor cells, release substances that stimulate other cells of the immune system and are involved in antigen presentation.

Malignant: Tending to become progressively worse and to result in death. Having the properties of anaplasia, invasion, and metastasis, said of tumors.

Malignant Fibrous Histiocytoma (MFH): A deeply situated tumor, especially on the extremities of adults.

Malignant Tumor: A mass of cancer cells. These cells have uncontrolled growth and will invade surrounding tissues and spread to distant sites of the body, setting up new cancer sites, a process called metastasis.

Mesenchymal: Relating to the mesenchyme, embryonic tissue of mesodermal origin. The mesoderm is the middle of the three germ layers and gives rise to the musculoskeletal, blood, vascular, and urinogenital systems, to connective tissue (including that of dermis) and contributes to some glands.

Metastasis: The transfer of disease from one organ to another due either to the transfer of pathogenic microorganisms (for example, tubercle bacilli) or to transfer of cells, as in malignant tumors. The capacity to metastasize is a characteristic of all malignant tumors.

Metastases. A growth of abnormal cells distant from the site primarily involved by the disease process.

Metastasize: To spread to another part of the body, usually through the blood vessels, lymph channels, or spinal fluid

Mitosis: A method of indirect division of a cell, consisting of a complex of various processes, by means of which the two daughter nuclei normally receive identical complements of the number of chromosomes characteristic of the somatic cells of the species.

Mitotic: Pertaining to mitosis.

Morphology: The configuration or structure (shape).

Moribundity: In a dying state; dying; at the point of death.

Mutagen: An agent that can cause an increase in the rate of mutation, includes X-rays, ultraviolet irradiation (260 nm), and various chemicals.

Necrosis: Morphological changes indicative of cell death.

Neoplasia/Neoplasm: New and abnormal growth of tissue, which may be benign or cancerous.

Oncology: The study of diseases that cause cancer.

P53 gene: A gene which encodes a protein that regulates cell growth and is able to cause potentially cancerous cells to destroy themselves.

Rhabdomyosarcoma: Malignant tumor (sarcoma) derived from striated muscle.

Sarcoma: Malignant tumor of soft tissue (tissue that connects, supports or surrounds other structures and organs of the body). Soft tissue includes muscles, tendons, fibrous tissues, fat, blood vessels, and nerves.

Schwannoma: A neoplasm [new and abnormal growth of tissue] originating from Schwann cells (of the myelin sheath) of neurons.

Teratology: The branch of embryology and pathology that deals with abnormal development and congenital malformations [i.e., the study of birth defects].

Toxicology: The scientific study of the chemistry, effects, and treatment of poisonous substances.

Tumor: An abnormal mass of tissue that results from excessive cell division that is uncontrolled and progressive, also called a neoplasm. Tumors perform no useful body function. They may be either benign (not cancerous) or malignant.

Tumorigenesis: The production of tumors.

Validity: The extent to which a measurement, test, or study measures what it purports to measure.

References

- Ace Animals Inc. Sprague Dawley. Available at: <http://aceanimals.com/SpragueDawley.htm>. Accessed September 27, 2007.
- Applied Digital Solutions Inc. Press Release. Applied Digital Solutions' VeriChip Corporation confirms that the Attorney General of Mexico and some of his staff have been 'chipped'. Available at: <http://www.adxs.com/pressreleases/2004-07-14.html>. Accessed October 24, 2007, July 14, 2004.
- Ball, DJ, et al. Evaluation of a microchip implant system used for animal identification in rats. *Laboratory Animal Science*. 1991;41(2):185–186.
- Banfield The Pet Hospital Press Release. Banfield applauds legislation promoting open pet microchip technology where all scanners read all chips. November 3, 2005.
- Biran, S, et al. Development of carcinoma of the breast at the site of an implanted pacemaker in two patients. *Journal of Surgical Oncology*. 2006;11(1):7–11.
- Blanchard, KT, et al. Transponder-induced sarcoma in the heterozygous p53+/- mouse. *Toxicologic Pathology*. 1999;27(5):519–527.
- Brand, KG. Cancer associated with asbestosis, schistosomiasis, foreign bodies or scars. In: Becker F, ed. *Cancer—A Comprehensive Treatise. Etiology: Chemical and Physical Carcinogenesis*: Plenum Press; 1982:671–676.
- Brand, KG, et al. Etiological factors, stages, and the role of the foreign body in foreign body tumorigenesis: A review. *Cancer Research*. 1975;35(2):279–286.
- British Small Animal Veterinary Association. Microchip Report 2003. Available at: http://www.bsava.com/VirtualContent/85185/Adverse_Reaction_Report_2003PDF.pdf. Accessed October 13, 2007.
- British Small Animal Veterinary Association. Microchip Report 2004. Available at: http://www.bsava.com/VirtualContent/85185/Adverse_Reaction_Report_2004PDF.pdf. Accessed October 13, 2007.
- Cascino, GD, et al. Breast cancer at site of implanted vagus nerve stimulator, *Neurology* (2007) 68:9. *Neurology*. 2007;68(9):703.
- Charles River Laboratory. Research Models and Services Catalog 2007.
- Dogster's For the Love of Dogs Blog. Comments posted in response to: "VeriChip Corporation microchipslinked to tumors, former presidential candidate Tommy Thompson linked to company". Available at: <http://dogblog.dogster.com/2007/09/13/verichip-corporation-microchips-linked-to-tumors-former-presidential-candidate-tommy-thompson-linked-to-company/>. Accessed October 18, 2007.
- Dutch Group Nijhof. Wel Of Niet Chippen? Available at: <http://www.invisio.nl/antichip/>. Accessed October 13, 2007.
- Elcock, LE, et al. Tumors in long-term rat studies associated with microchip animal identification devices. *Experimental and Toxicologic Pathology*. 2001;52:483–491.
- Jackson Laboratory, The. Jax Mice Data Sheet: Strain Name CBA/J. Available at: <http://jaxmice.jax.org/strain/000656.html>. Accessed October 10, 2007.
- Jansen, JA, et al. Biological and migrational characteristics of transponders implanted into beagle dogs. *Veterinary Record*. 1999;145:329–333.
- Jennings, T, et al. Angiosarcoma associated with foreign body material. A report of three cases. *Cancer*. 1988;62(11):2436–2444.
- Johnson, K. Foreign-body Tumorigenesis: Sarcomas Induced in Mice by Subcutaneously Implanted Transponders. *Toxicologic Pathology*. 1996;33(5):619. Abstract #198.
- Kasper, DL, et al. Soft tissue sarcomas. *Harrison's Principles of Internal Medicine 16th Ed.*: McGraw-Hill Professional; 2004.
- Keel, SB, et al. Orthopaedic implant-related sarcoma: A study of twelve cases. *Modern Pathology*. 2001;14(10):969–977.
- Le Calvez, S, Perron-Lepage, M-F, Burnett, R. Subcutaneous microchip-associated tumours in

- B6C3F1 mice: A retrospective study to attempt to determine their histogenesis. *Experimental and Toxicologic Pathology*. 2006;57:255–265.
- Lewan, T. Chip Implants Linked to Animal Tumors. Associated Press. September 8, 2007.
- Martin-Negrier, M-L, et al. Primitive malignant fibrous histiocytoma of the neck with carotid occlusion and multiple cerebral ischemic lesions. *Stroke*. 1996;27:536–537.
- McCarthy, PE, et al. Liposarcoma associated with glass foreign body in a dog. *Journal of the American Veterinary Medical Association*. 1996;209:612–614.
- McCullough, S. *Senior Dogs for Dummies*: John Wiley & Sons; 2004.
- McIntyre, L. French bulldog is catalyst for investigation of microchip-cancer connection. September 8, 2007. Available at: http://www.spsychips.com/blog/2007/09/rfid_cancer_story_catalyst_lov.html. Accessed October 18, 2007.
- Milman, HA, Weisburger, EK, eds. *Handbook of Carcinogen Testing, Second Edition*. Park Ridge, NJ: Noyes Publications; 1994.
- Morrison, BA. Soft tissue sarcomas of the extremities. *Proc (Bayl Univ Med Cent)*. 2003;16(3):285–290.
- Murasugi, E, et al. Histological reactions to microchip implants in dogs. *The Veterinary Record*. September 13 2003:328.
- National Women's Health Resource Center. Clinical Trials Overview. Available at: http://findarticles.com/p/articles/mi_m0PWR/is_2005_August_9/ai_n17214944/p. Accessed October 10, 2007.
- Palmer, TE, et al. Fibrosarcomas associated with passive integrated transponder implants. *Toxicologic Pathology*. 1998;26:170.
- Platt, S, et al. Spinal cord injury resulting from incorrect microchip placement in a cat. *Journal of Feline Medicine & Surgery*. 2006;9(2):157–160.
- Rao, GN, Edmondson, J. Tissue reaction to an implantable identification device in mice. *Toxicologic Pathology*. 1990;18(3):412–416.
- Rasmussen, K, et al. Male breast cancer from pacemaker pocket. *Pacing and Clinical Electrophysiology*. 1985;8(5):761–763.
- Rothenberger-Janzen, K, Flueckiger, A, Bigler, R. Carcinoma of the breast and pacemaker generators. *Pacing and Clinical Electrophysiology*. 1998;21(4):769–771.
- Simonsen Laboratories. Fischer 344. Available at: <http://www.simlab.com/products/fischer344.html>. Accessed October 5, 2007.
- Tillmann, T, et al. Subcutaneous soft tissue tumours at the site of implanted microchips in mice. *Experimental and Toxicologic Pathology*. 1997;49:197–200.
- Trivedi, B. Toxic cocktail. *New Scientist Magazine*. Sept. 1 2007;2619:44–47.
- Vascellari, M, Mutinelli, F. Fibrosarcoma with typical features of postinjection sarcoma at site of microchip implant in a dog: Histologic and immunohistochemical study. *Veterinary Pathology*. 2006;43:545–548.
- Vascellari, M, et al. Liposarcoma at the site of an implanted microchip in a dog. *The Veterinary Journal*. 2004;168:188–190.
- VeriChip Corp. Press Release. RFID gets under their skin, March 1, 2006. Available at: <http://www.verichipcorp.com/news/1141257941>. Accessed October 24, 2007.
- Whitley, E, Ball, J. Statistics review 4: Sample size calculations. *Critical Care*. 2002;6(4):335–341.